

Diagnostic Exercise

From the CL Davis/ Foundation

Question sheet

Case #: **167** Month: **June** Year: **2021**

Contributors: Fábio S. Mendonça¹, DVM, MSc, PhD. Silvio M. C. Fonseca¹, DVM, MSc student. Givaldo B. Silva-Filho¹, DVM, MSc student. Hisadora A.S.C. Bom¹, DVM, MSc student. Nathalia S. Wicpolt¹, DVM, MSc, PhD. Laboratory of Animal Diagnosis, Federal Rural University of Pernambuco. mendoncafs@yahoo.com.br

Clinical History: A 3-year-old Santa Ines sheep presented loss of condition, pale mucous membranes, opaque and bristly hair and an increased volume of the right mandible. The owner said that a purulent secretion was coming out through the mass, but after an antibiotic therapy, there was improvement and partial regression of the lesion. At clinical examination, the mass was firm and the sheep showed signs of pain when examined physically. No purulent content was observed at the site of the lesion, but there was a scar in the skin, which was interpreted as a consequence of an abscess. The sheep was euthanized and a necropsy was performed.

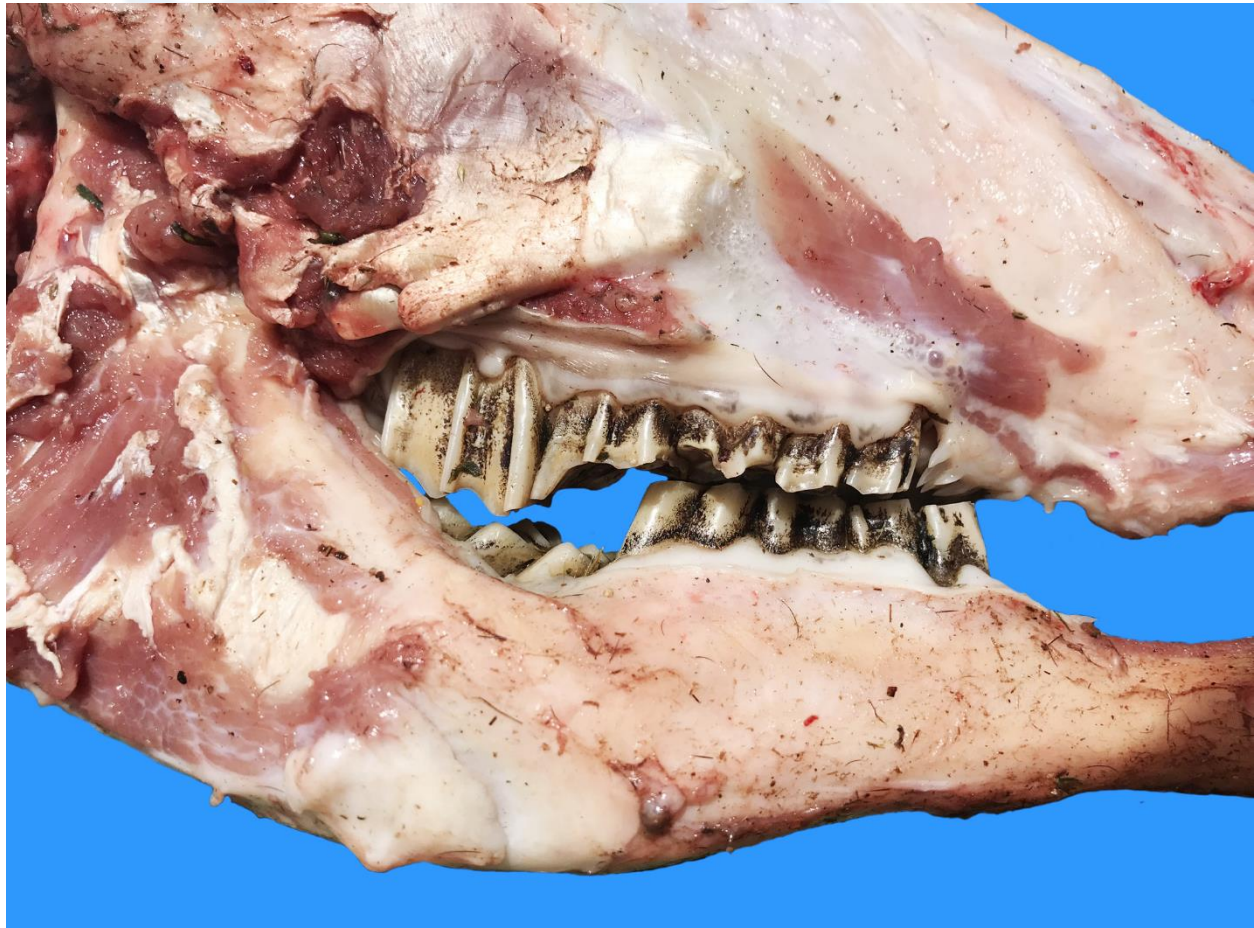

Figure 1

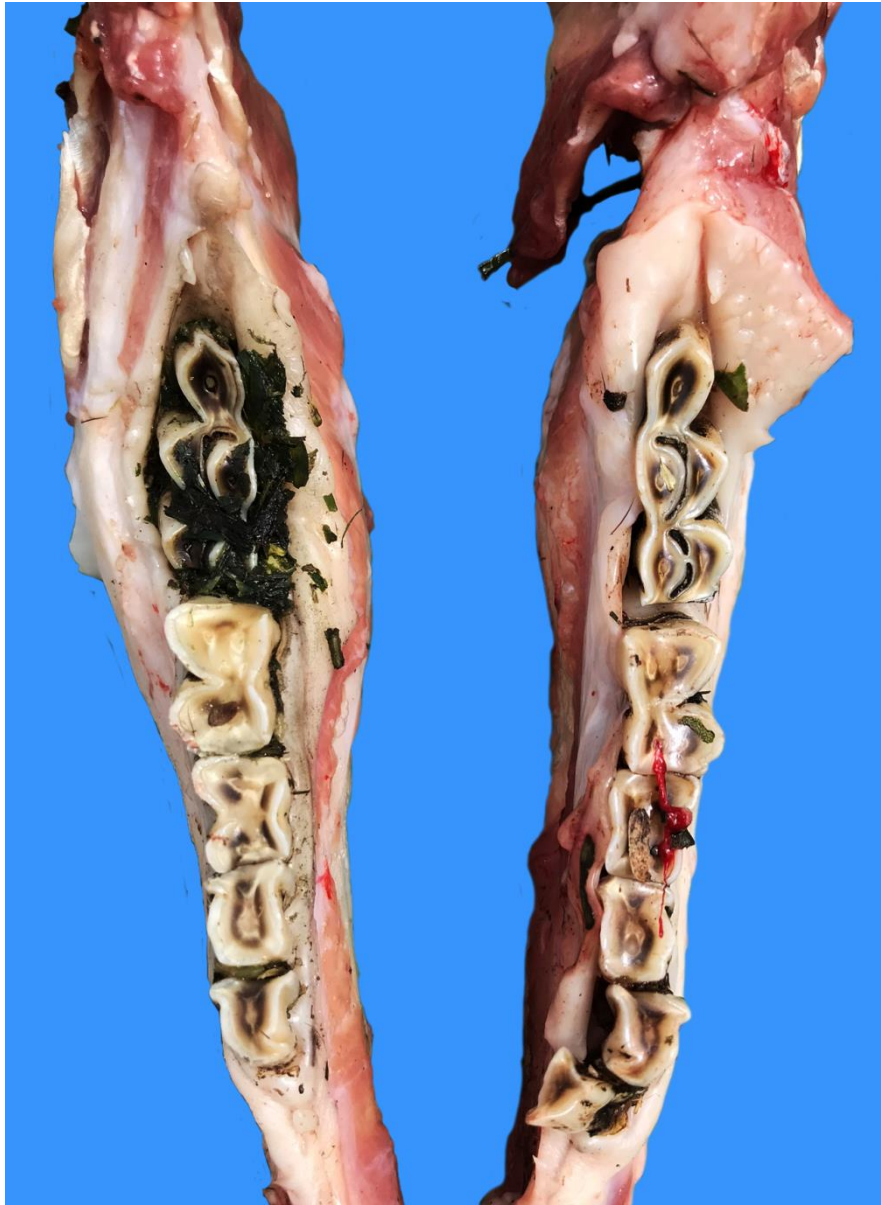

Figure 2

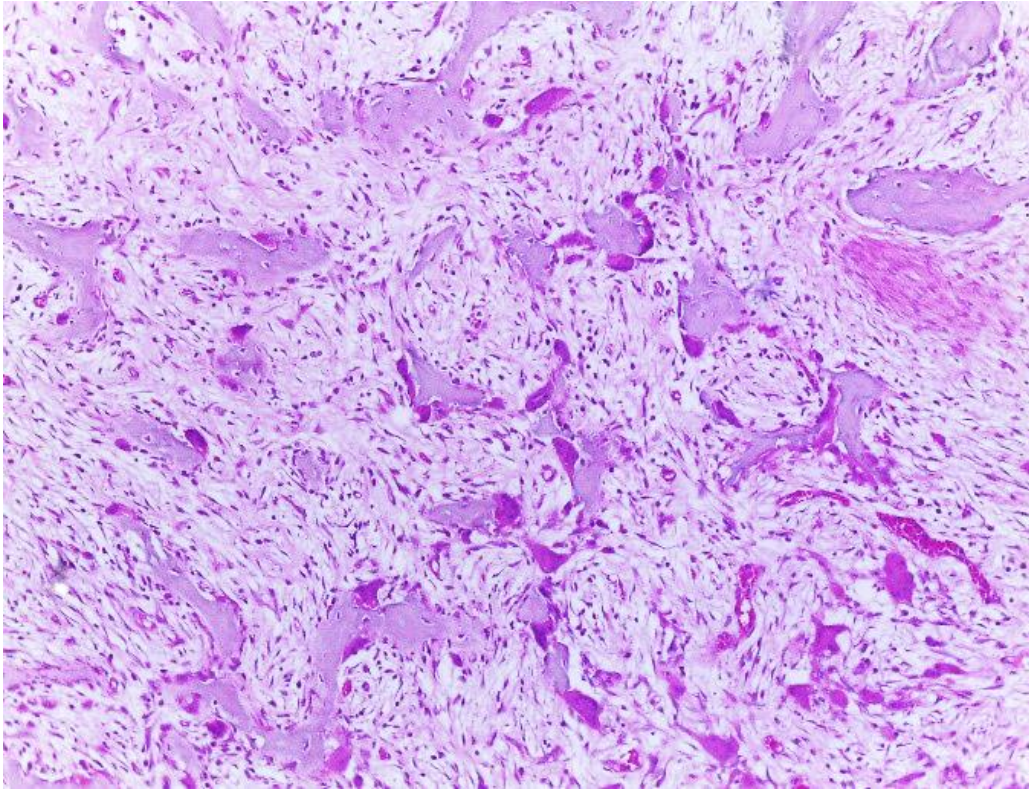


Figure 3

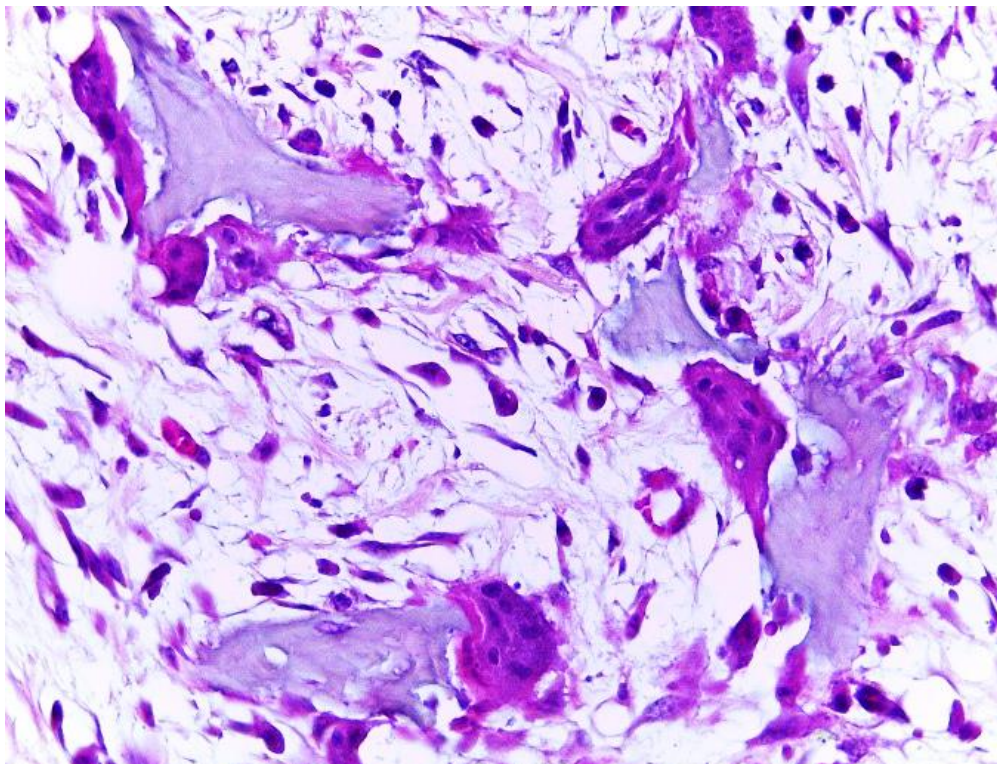


Figure 4

Follow up Questions:

- *Gross and microscopic description*
- *Morphologic diagnosis*
- *Name of the condition*
- *Pathogenesis.*

The Diagnostic Exercises are an initiative of the **Latin Comparative Pathology Group** (LCPG), the Latin American subdivision of The Davis-Thompson Foundation. These exercises are contributed by members and non-members from any country of residence. Consider submitting an exercise! A final document containing this material with answers and a brief discussion will be posted on the CL Davis website http://www.cldavis.org/diagnostic_exercises.html Editorial Committee.

Associate Editor for this Diagnostic Exercise: Ingeborg Langohr

Editor-in-chief: Claudio Barros