



Diagnostic Exercise

From The Davis-Thompson Foundation*

Case #278; Month March; Year: 2026

Question sheet

Contributors: Cassandra M. Powers. California Animal Health and Food Safety Laboratory, Davis, CA and Purdue University, West Lafayette, IN.

Author for correspondence cmpowers@ucdavis.edu

History: A placenta from a mare following parturition was submitted for evaluation. The foal was reported to be unusually weak at birth but otherwise grossly normal with no clinical abnormalities. The mare was treated with antibiotics prior to parturition.

Gross Findings: On the surface of the center of the body of the placenta is a poorly demarcated focal area composed of thick, tan, sticky, brown, mucoid exudate on the avillous region (**Figure 1**).

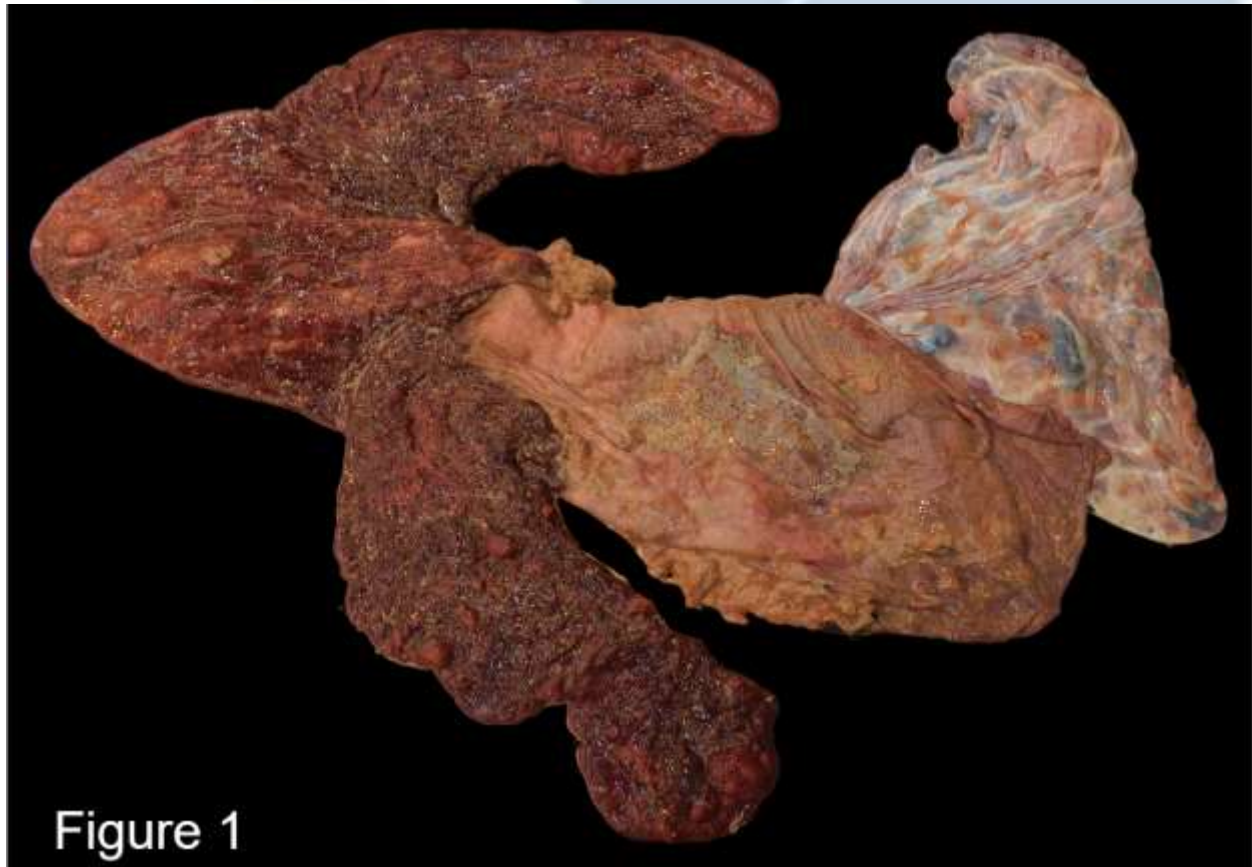


Figure 1

Histopathology:

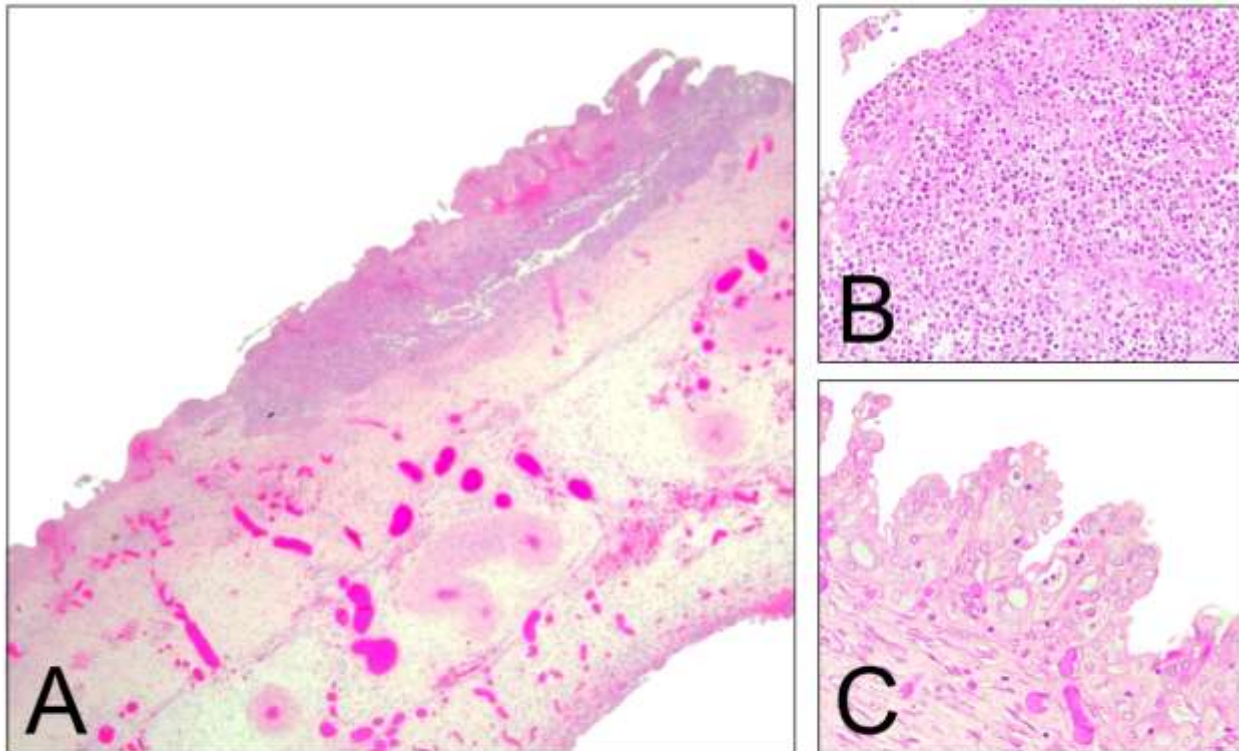


Figure 2

Follow-up questions:

- *Morphologic diagnosis:*
- *Etiology:*
- *Name the disease:*

*The Diagnostic Exercises are an initiative of the Latin Comparative Pathology Group (LCPG), the Latin American subdivision of The Davis-Thompson Foundation (DTF). These exercises are contributed by members and non-members from any country of residence. Consider submitting an exercise! A final document containing this material with answers and a brief discussion will be posted on the DTF website.

(<https://davisthompsonfoundation.org/diagnostic-exercise/>)

Associate Editor for this Diagnostic Exercise: Franklin Riet-Correa
Editor-in-chief: Claudio Barros