



Diagnostic Exercise

From The Davis-Thompson Foundation*

Case: **218**; Month: **August**; Year: **2023**

Question Sheet

Contributors: Shakirat A. Adetunji, DVM, MS, PhD^{1,2} sadetunji@vet.k-state.edu;
Brittany L. Rasche DVM, DACVP^{1,2}

¹Department of Diagnostic Medicine/Pathobiology. College of Veterinary Medicine, Kansas State University, Manhattan, KS, USA

²Kansas State Veterinary Diagnostic Laboratory, Manhattan, KS, USA

Clinical History:

An adult female Boer goat gave birth to two weak kids, one of which died within one hour after birth. Hard, firm caruncles were reportedly palpated in the uterus of this doe. The dead neonate and associated placenta were submitted to the Kansas State Veterinary Diagnostic Laboratory for necropsy and ancillary diagnostic testing.

One other doe on the farm had recently given birth to an apparently healthy kid as well as a mummified fetus. Two other does on the farm had kidded that season with no apparent issues.

Gross Findings:

The placenta was diffusely moderately thickened and gelatinous (**Figure 1**). Most of the cotyledons had multiple, randomly distributed, pinpoint, tan foci. The intercotyledonary areas had multifocal to coalescent pale tan plaques. Moderate amount of thick, tan, cloudy, exudate was adherent along the chorionic surface of the placenta.

No gross lesions were observed on postmortem examination of the neonate.

Gross Image:

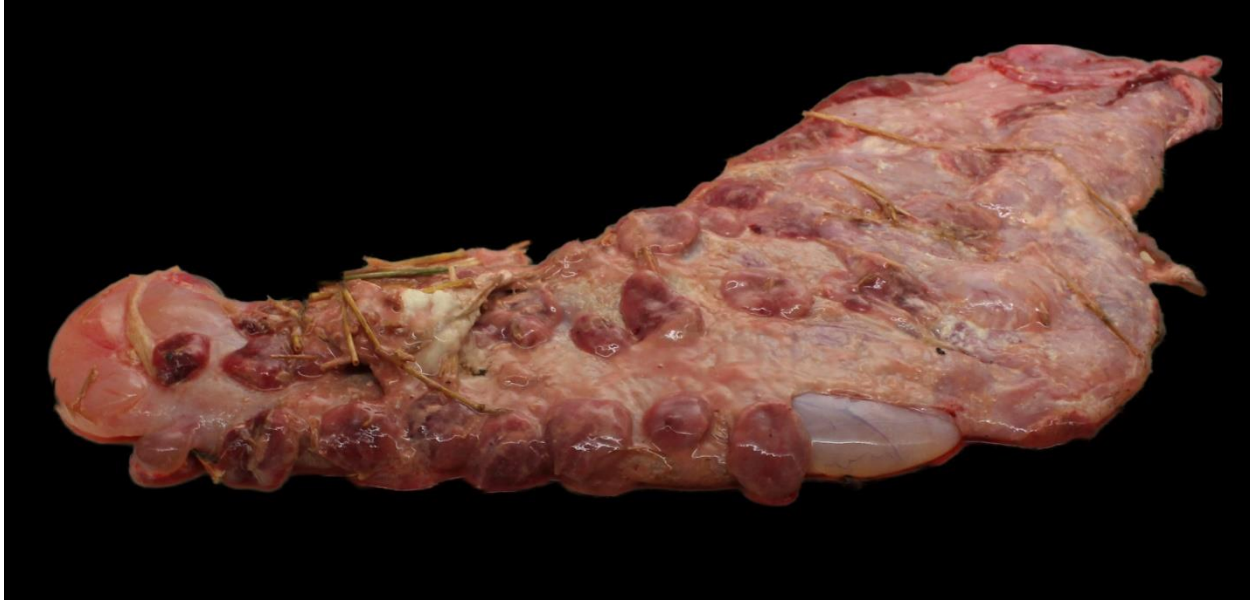

Figure 1

Microscopic Images:

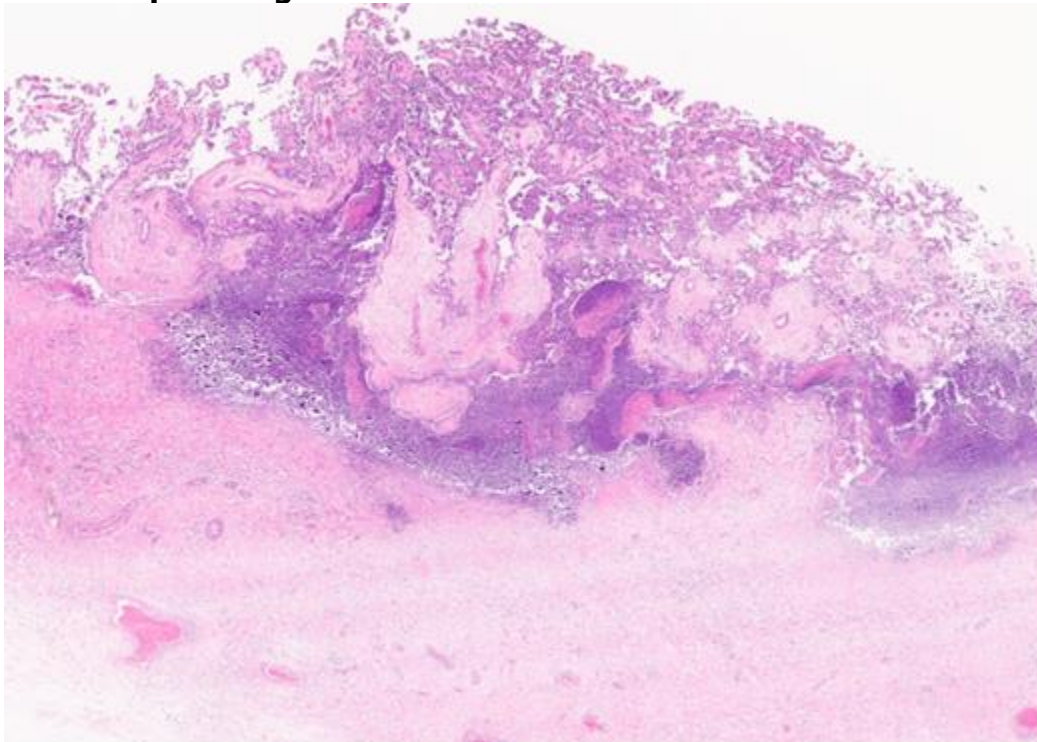


Figure 2

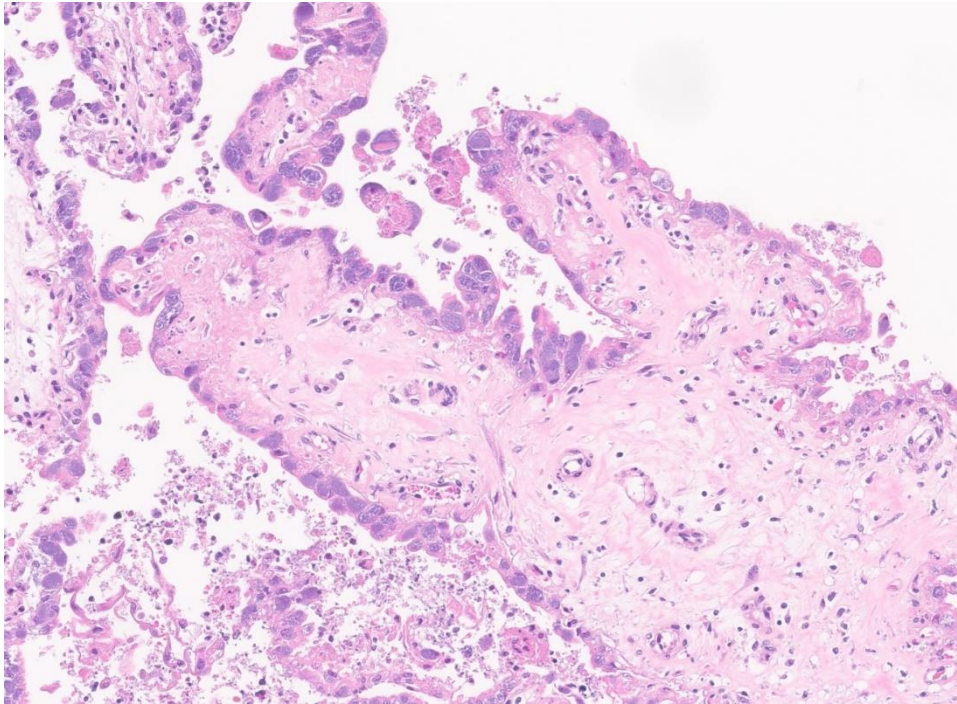


Figure 3

Follow-up Questions:

- *Gross morphologic diagnosis?*
- *Histopathologic diagnosis?*
- *Potential etiologies?*
- *Additional diagnostic tests?*

*The Diagnostic Exercises are an initiative of the Latin Comparative Pathology Group (LCPG), the Latin American subdivision of The Davis-Thompson Foundation. These exercises are contributed by members and non-members from any country of residence. - Consider submitting an exercise! - A final document containing this material with answers and a brief discussion will be posted on the CL Davis website (<https://davisthompsonfoundation.org/diagnostic-exercise/>).

Associate Editor for this Diagnostic Exercise: Ingeborg Langohr
Editor-in-chief: Claudio Barros.