



DIAGNOSTIC EXERCISE

From The Davis-Thompson Foundation*

Case #: 268; Month: September; Year: 2025

Question Sheet

Contributors: Adriana L. Stigger^{*1}, Saulo P. Pavarini², Irene Guterra¹, Francine F. Pereira¹, Milena Carolina Paz², Emanoelly M. S. da Silva², Claudio S.L. Barros³, Daniel R. Rissi⁴

¹Laboratory of Veterinary Pathology, Centro Universitário da Região da Campanha (Urcamp), Alegrete, RS, Brazil

²Setor de Patologia Veterinária, Faculdade de Medicina Veterinária, Universidade Federal do Rio Grande do Sul (UFRGS), Porto Alegre, RS, Brazil.

³Laboratory of Anatomic Pathology, School of Veterinary Medicine and Animal Sciences, Federal University of Mato Grosso do Sul, Campo Grande, MS, Brazil.

⁴Athens Veterinary Diagnostic Laboratory, Department of Pathology, College of Veterinary Medicine, University of Georgia, Athens GA, USA

*Corresponding author: adrianaluckestigger@gmail.com

Clinical history: Cases of neurologic disease occurred in a sheep farm in late 2023, with a surge in cases in July 2024. The disease affected lambs more frequently. Clinical signs lasted from 7 days to 1 month and include blindness, ataxia, lateral deviation of the head, circling, and reflux of ruminal contents through the nose. One animal had exophthalmos. There were several dogs on the farm. The total number of sheep on the farm was 100, 50 of which were in the group where the disease occurred. Six of those 50 had clinical signs and died. All sheep were free in the pasture.

Autopsy findings: A 2.5-year-old sheep was autopsied. A 5 cm in diameter cyst compressed the right cerebral hemisphere. The overlying membranous skull bone of the skull in this site was marked thinned due to compression by the cyst (Fig. 1A). The cyst was formed by a thin transparent membrane and filled with clear fluid; numerous white protoscolices internally adhered to the cyst membrane. (Fig. 1B). Due to the space-occupying effect of the cyst, there was flattening of the cerebral gyri and caudal displacement of part of the occipital lobe of the brain under the tentorial space and into the caudal fossa (subtentorial herniation), with consequent compression of the cerebellum (Fig.2).

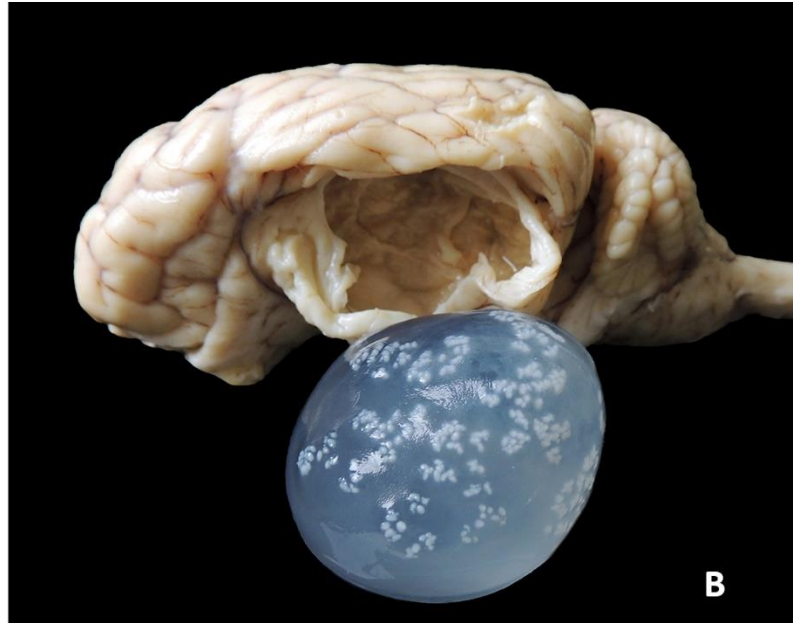
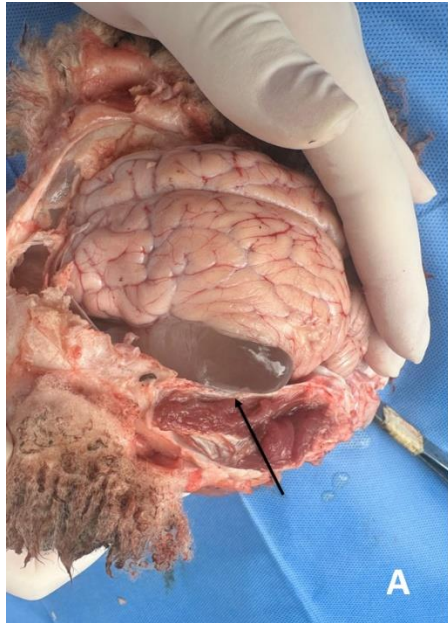


Figure 1. Brain, sheep.

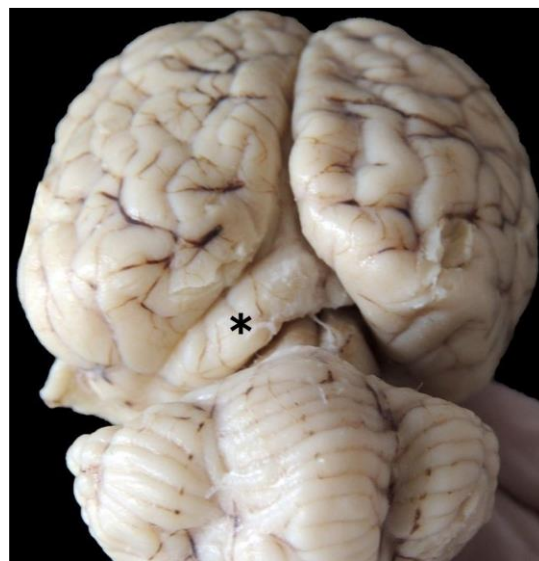

Figure 2. Brain, sheep

Follow-up questions?

- *Morphologic diagnosis?*
- *Etiology?*
- *Name of the condition?*

*The Diagnostic Exercises are an initiative of the Latin Comparative Pathology Group (LCPG), the Latin American subdivision of The Davis-Thompson Foundation (DTF). These exercises are contributed by members and non-members from any country of residence. Consider submitting an exercise! A final document containing this material with answers and a brief discussion will be posted on the DTF website.

(<https://davisthompsonfoundation.org/diagnostic-exercise/>)

Associate Editor for this Diagnostic Exercise: Daniel Rissi

Editor-in-chief: Claudio Barros