



Diagnostic Exercise

From The Davis-Thompson Foundation*

Question Sheet

Case: **192**; Month: **July**; Year: **2022**

Contributors: Eleonora Morrell¹, MV, PhD ; Andrea Fiorentino¹, MV, PhD; Enrique Louge Uriarte¹, MV, PhD; Valeria Scioli¹; Timoteo Tessi¹ MV; Prando Moore^{1,2}, MV, PhD; Germán Cantón, MV, PhD. ¹National Institute of Agricultural Technology, Balcarce, Argentina. ²Institute of Innovation for Agricultural Production and Sustainable Development, Balcarce, Argentina. morrell.eleonora@inta.gob.ar

Clinical History: A three-month gestation bovine fetus and the placenta from a Holstein aborted cow were submitted to determine the cause of the abortion.

Necropsy findings: No gross abnormalities were observed in the fetus or placenta.

Microscopic Images:

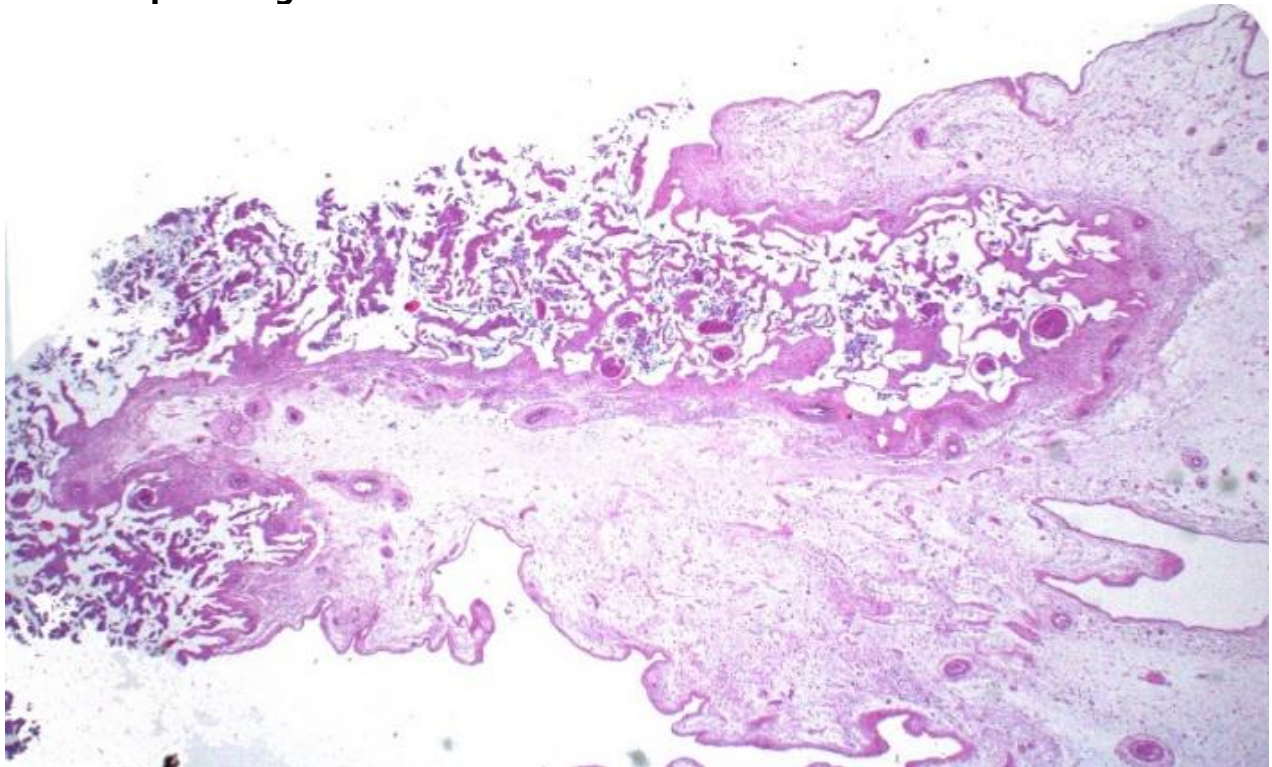


Fig. 1. Placenta. HE (Photo courtesy of F. Uzal)

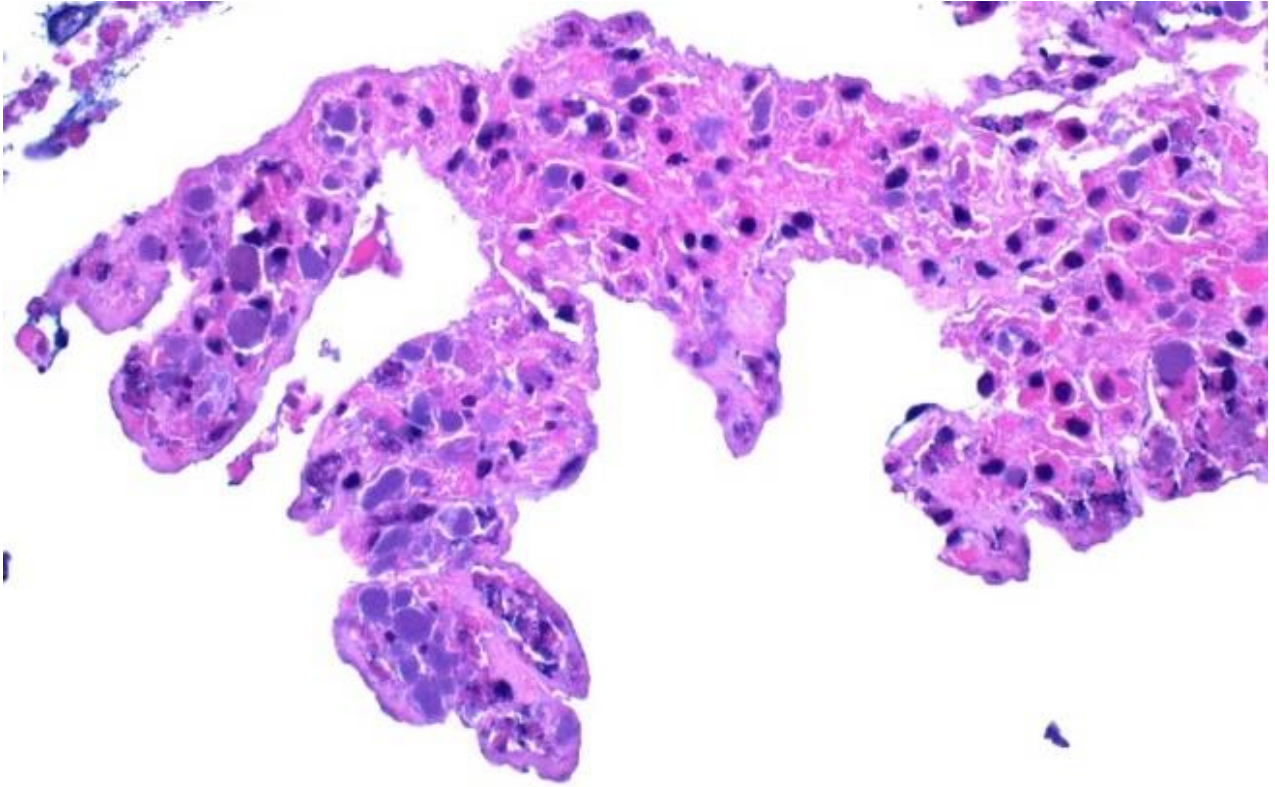


Fig. 2. Placenta. HE (*Photo courtesy of F. Uzal*)

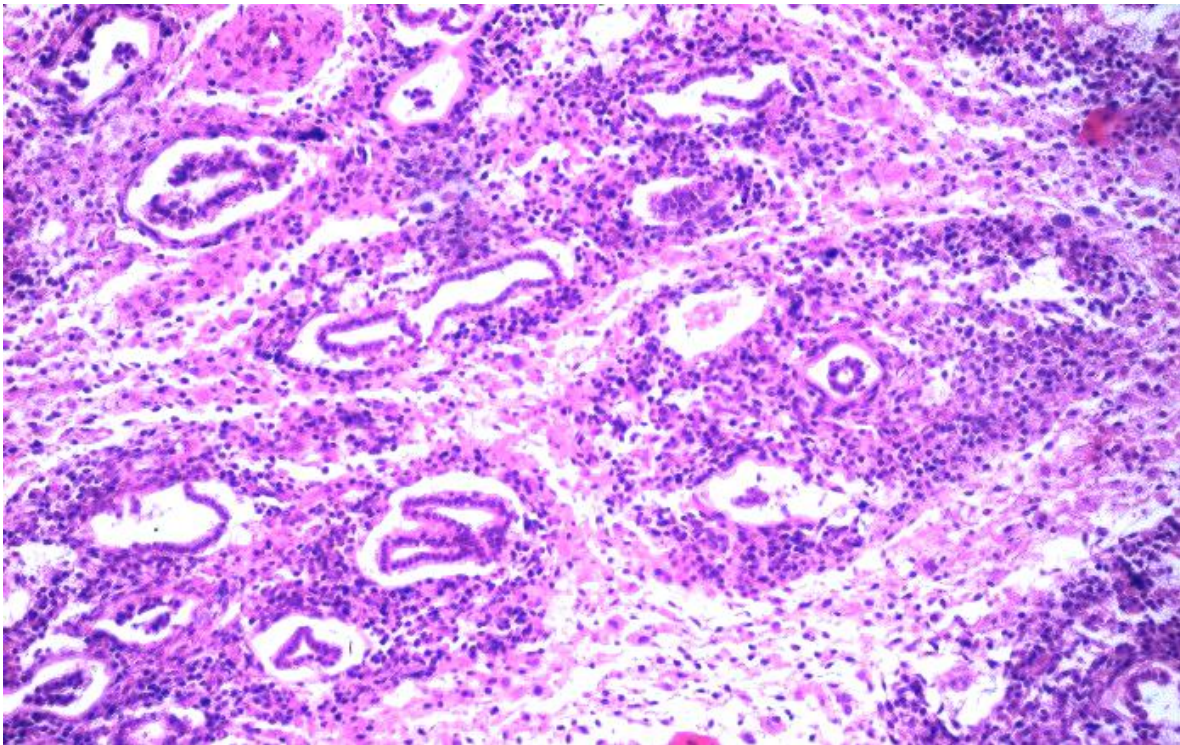


Fig.3. Fetal lung. HE.

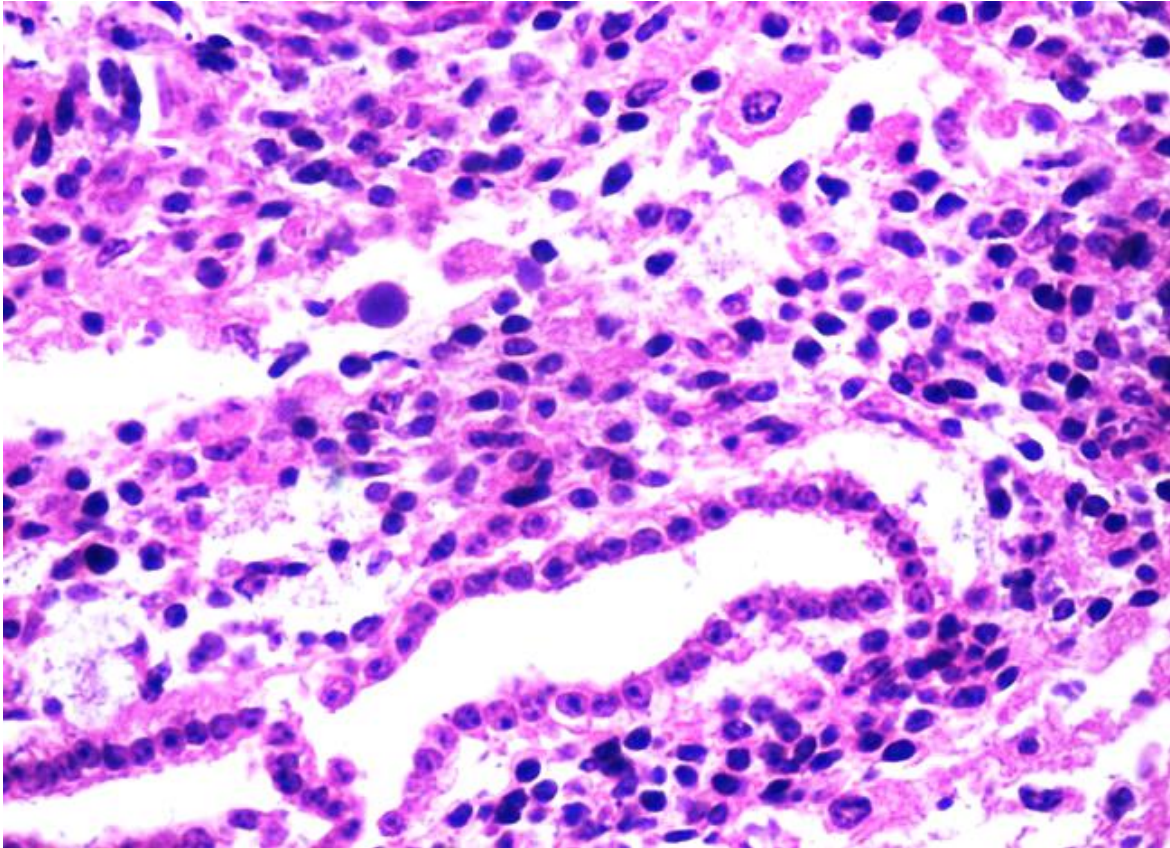


Fig. 4. Fetal lung. HE.

Follow-up questions:

1. *Two morphologic diagnoses?*
2. *Etiology?*
3. *Special stains frequently employed for the identification of the organisms?*
4. *Confirmatory diagnostic technique?*

*The Diagnostic Exercises are an initiative of the Latin Comparative Pathology Group (LCPG), the Latin American subdivision of The Davis-Thompson Foundation. These exercises are contributed by members and non-members from any country of residence. - Consider submitting an exercise! - A final document containing this material with answers and a brief discussion will be posted on the CL Davis website (http://www.cldavis.org/diagnostic_exercises.html)

Associate Editor for this Diagnostic Exercise: Francisco Uzal
Editor-in-chief: Claudio Barros