



Diagnostic Exercise

From the CL Davis/SW Thompson Foundation

Case # 272; Month: **November**; Year: **2025**

Question Sheet

Contributors: Tatiana Paz¹, Eileen Henderson², Javier Asín² and Francisco A. Uzal².

¹Veterinary Microbiology and Molecular Biology Laboratory, Veterinary Medicine Faculty, Federal University of Mato Grosso, MT, Brazil. ²California Animal Health and Food Safety Laboratory System, San Bernardino Branch, School of Veterinary Medicine, University of California-Davis, San Bernardino, CA, USA.

Corresponding Author: tpazc@unal.edu.co

Clinical history and examination: A two-day-old black and white pygmy goat kid was presented to the California Animal Health and Food Safety Laboratory – San Bernardino Branch, for euthanasia and necropsy with a history of what appeared to be a fluctuant mass under the skin of the ventral side of the neck. On clinical examination, an approximately 10 cm in diameter, fluid-filled structure was palpated under the skin along the ventral aspect of the neck (Fig 1). The goat kid had pronounced dyspnea and distress particularly during palpation. Euthanasia was performed with an overdose of barbiturate and a full necropsy was performed.

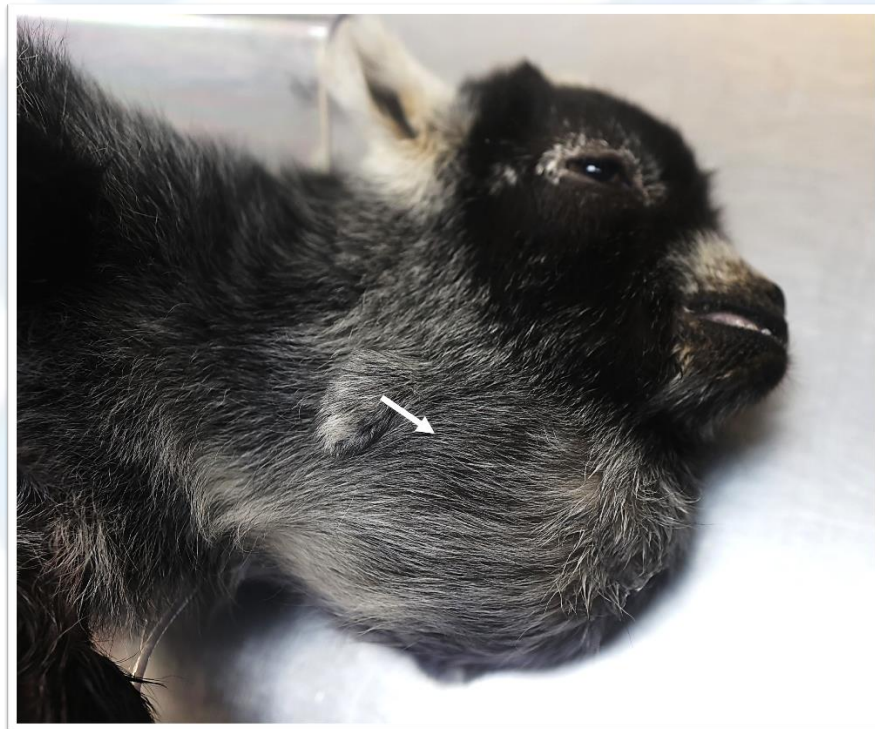

Figure 1.

Necropsy findings: Euthanasia was performed with an overdose of barbiturate and a full necropsy was performed. Dissection of the neck revealed a cyst that was compressing the adjacent esophagus and trachea. The cyst contained approximately 200 ml of tan cloudy fluid. Upon sectioning the cyst, a soft white material was observed, loosely adhered to the inner wall of it (Fig 2). No other significant gross abnormalities were detected in the rest of the carcass.

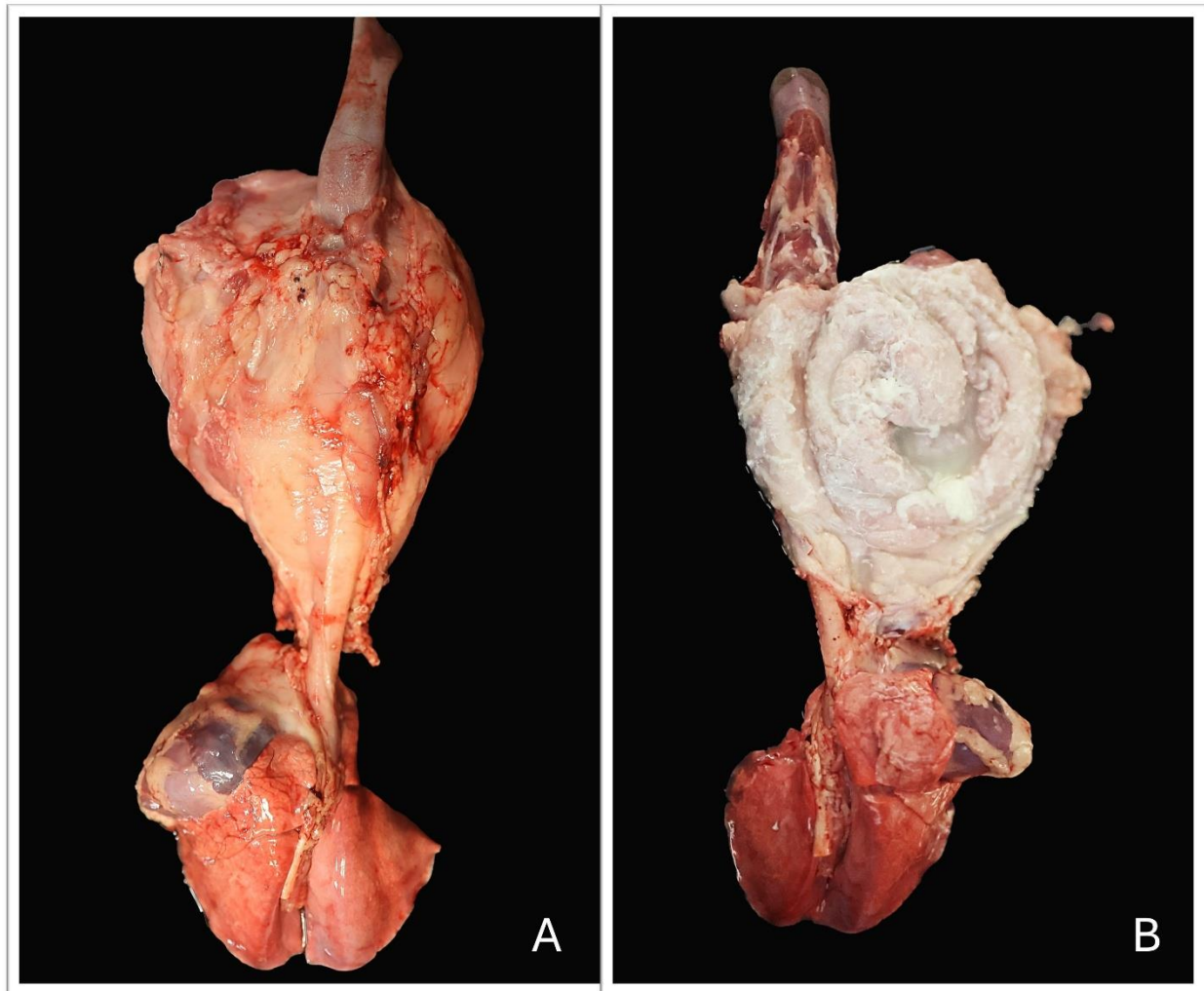


Figure 2.

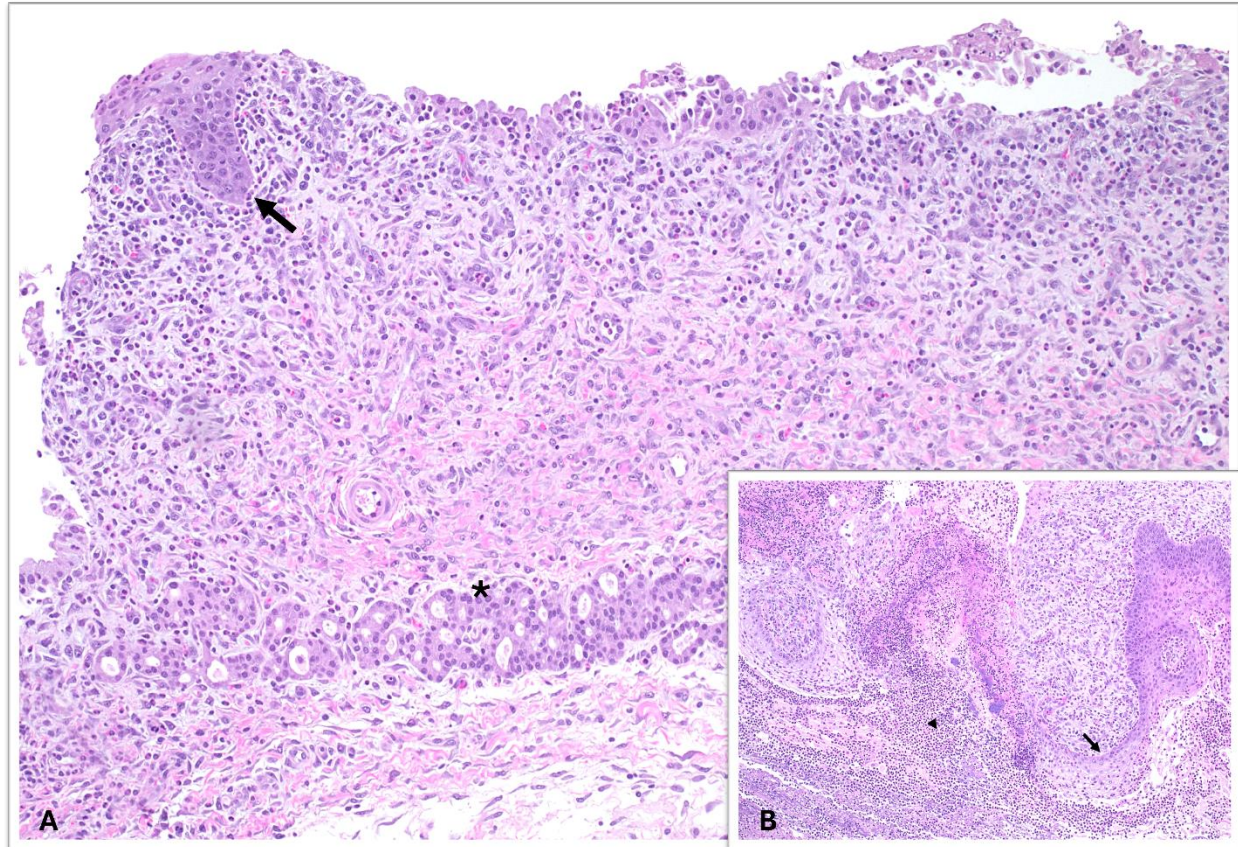


Figure 3.

Follow up questions

- *Histological findings:*
- *Pathological condition*
- *Most likely differential diagnoses:*

*The Diagnostic Exercises are an initiative of the Latin Comparative Pathology Group (LCPG), the Latin American subdivision of The Davis-Thompson Foundation. These exercises are contributed by members and non-members from any country of residence. Consider submitting an exercise! A final document containing this material with answers and a brief discussion will be posted on the CL Davis website (<https://davisthompsonfoundation.org/diagnostic-exercise/>).

Associate Editor for this Diagnostic Exercise: Francisco Uzal

Editor-in-chief: Claudio Barros