



Diagnostic Exercise

From The Davis-Thompson Foundation*

Case # **270**; Month: **October**; Year: **2025**

Question Sheet

Contributors: M Kevin Keel¹, Elizabeth C. Rose^{2,3}, Celeste M Morris^{2,4}.

¹Department of Pathology, Microbiology and Immunology (Keel); School of Veterinary Medicine; University of California, Davis; Davis, CA 95616

²William R. Pritchard Veterinary Medical Teaching Hospital; School of Veterinary Medicine; University of California, Davis; Davis, CA. 95616

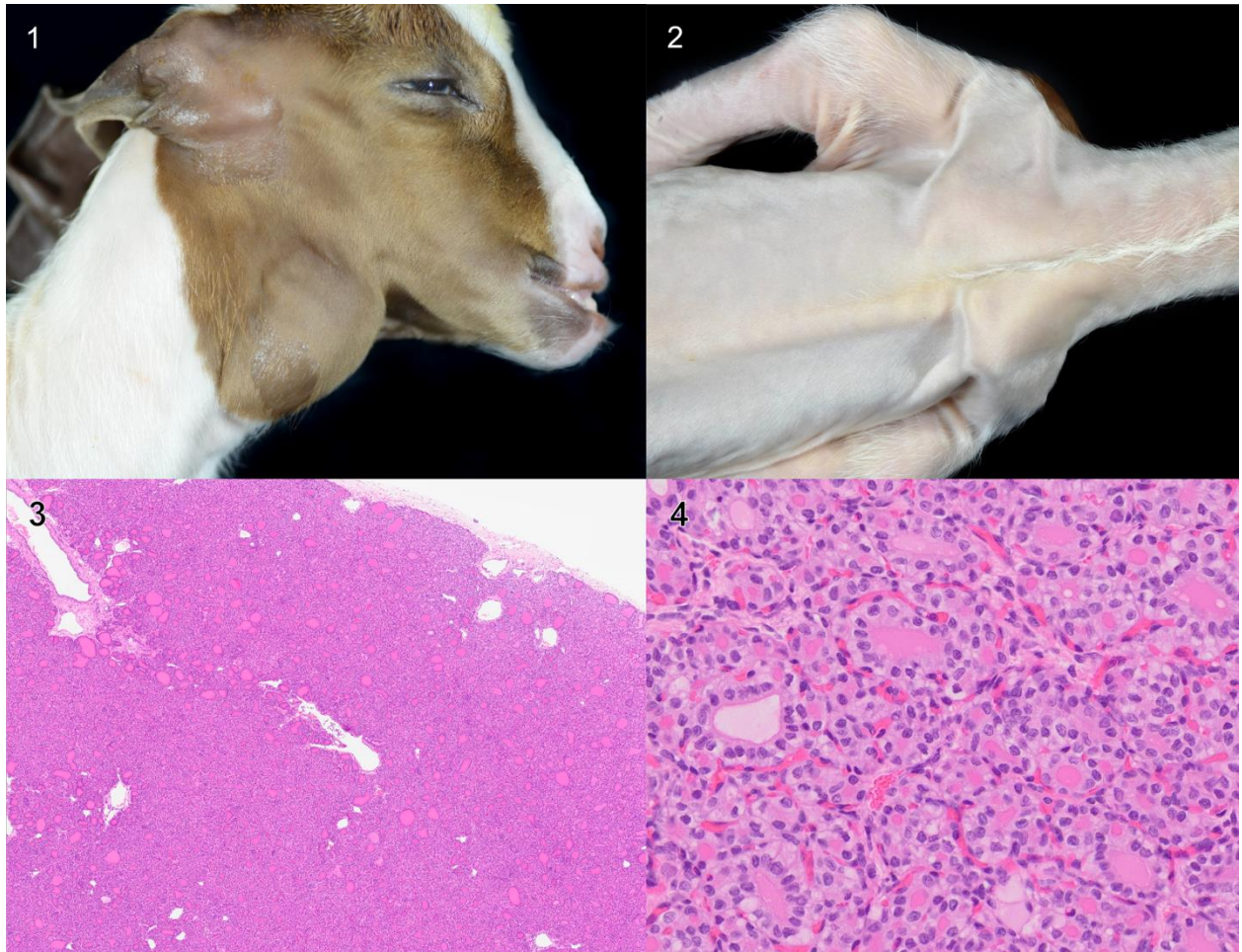
³Current address: Department of Population Health and Pathobiology, College of Veterinary Medicine, North Carolina State University, Raleigh, NC 27607

⁴Current address: Department of Veterinary Medicine and Surgery; College of Veterinary Medicine; University of Missouri; Columbia, MO 65211

Corresponding author: mkkeel@ucdavis.edu

History: Nine, adult, female Boer goats were presented to the University of California, Davis, Veterinary Medical Teaching Hospital for timed artificial insemination. To synchronize their estrous cycles, the owner gave each doe 7.5 mg dinoprost tromethamine (Lutalyse®) intramuscularly 12 hours prior to presentation and 24 hours prior to removal of the doe's progesterone controlled intravaginal drug release device (EAZI-BREED™ CIDR®). Approximately 52 hours after prostaglandin administration, one of the does delivered two live kids, one female and one male, without complication. The neonates were unexpectedly premature by approximately two weeks. Both kids exhibited bilateral, smooth swelling at the laryngotracheal junction and generalized alopecia. Both kids were euthanized, and they were sent to the UC Davis Anatomic Pathology Service for necropsy.

Necropsy Findings: Both animals had marked gular swelling that corresponded to palpably enlarged thyroid glands (Fig 1). Each also had a soft, short, hair coat, and these changes were most prominent along the dorsum, ventrum, flanks and external aspects of the pinnae (Fig 2). The thyroid glands were approximately 3 x 1.5 x 1 cm in the male and 4 x 2.5 x 2 cm in the female. On cut section, the glands were smooth, firm and dark red. The tongues of both kids were expanded by edema to a maximal thickness of 1 cm. In the female, the loose connective tissue surrounding the trachea and esophagus was also expanded by clear fluid (edema). The mandible of the male extended approximately 1 cm beyond the rostral aspect of the maxilla (mild prognathism). Both kids had scant internal and subcutaneous adipose tissue. Samples of the thyroid glands were submitted for histopathology (Figs 3 and 4).



Figures 1-4

Follow-up questions:

- *Morphologic diagnosis:*
- *Name the disease:*

*The Diagnostic Exercises are an initiative of the Latin Comparative Pathology Group (LCPG), the Latin American subdivision of The Davis-Thompson Foundation (DTF). These exercises are contributed by members and non-members from any country of residence. Consider submitting an exercise! A final document containing this material with answers and a brief discussion will be posted on the DTF website.

(<https://davisthompsonfoundation.org/diagnostic-exercise/>)

Associate Editor for this Diagnostic Exercise: Franklin Riet-Correa

Editor-in-chief: Claudio Barros