



# Diagnostic Exercise

## From The Davis-Thompson Foundation\*

### *Question Sheet*

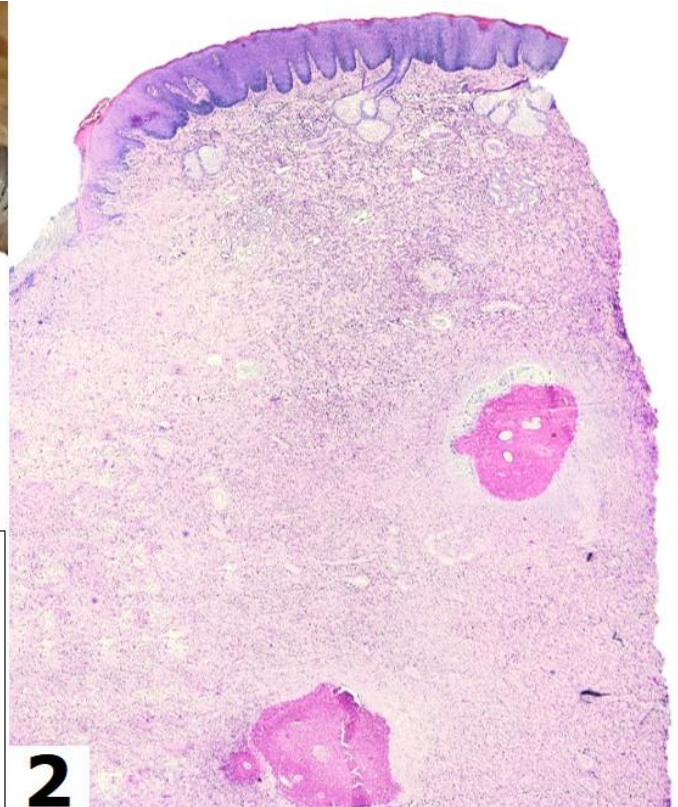
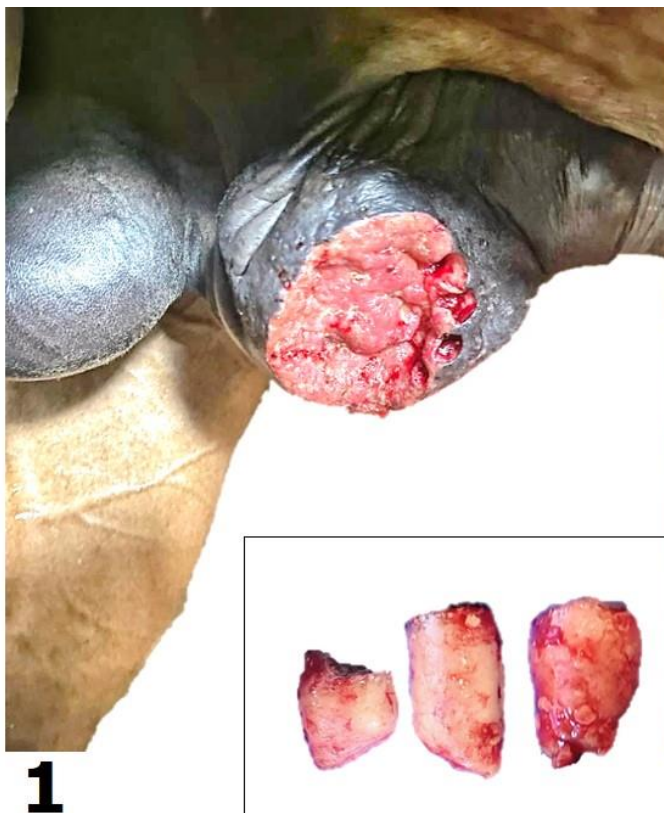Case: **195**; Month: **August**; Year: **2022**

**Contributors:** Felipe Martins Negreiros Navolar<sup>1</sup>, DVM, MSc Student; Julio Adriano Kioquetta<sup>2</sup>, DVM; Marcela dos Santos Ribeiro<sup>2</sup>, DVM; Antônio Cezar de Oliveira Dearo<sup>2</sup>, DVM, MSc, DVSc, Tatiane Cargnin Faccin<sup>1</sup>, DVM, MSc, PhD.

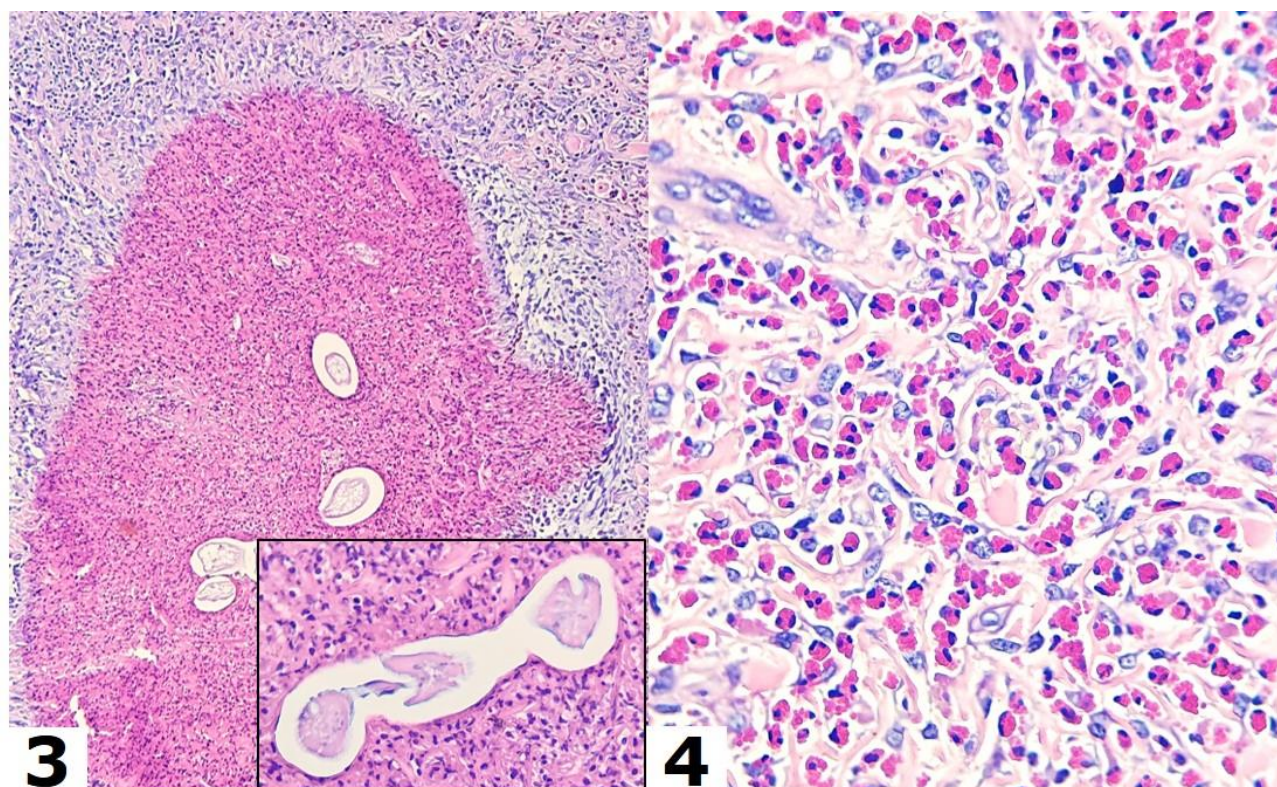
<sup>1</sup> Laboratory of Animal Pathology, Universidade Estadual de Londrina (UEL), Londrina, Paraná, Brazil. Corresponding author: [tatifaccin@hotmail.com](mailto:tatifaccin@hotmail.com)

<sup>2</sup> Large Animal Internal Medicine and Surgery, Universidade Estadual de Londrina (UEL), Londrina, Paraná, Brazil.

**Clinical history:** A 4-year-old male Quarter Horse was unsuccessfully treated for a circumscribed and ulcerated mass of unknown evolution located lateral to the prepuce (Fig. 1).



**Figure 1.** Gross appearance of the ulcerated lesion lateral to the prepuce. *Inset:* Samples collected by punch biopsy. **Figure 2.** Skin, horse. Hematoxylin and eosin (HE), 2x.



**Figure 3.** Skin, horse. HE, 20x. *Inset:*40x. **Figure 4.** Skin, horse. HE, 40x.

**Follow-up questions:**

- *Morphologic diagnosis*
- *Etiologic diagnosis*
- *Possible causes*
- *Disease*

**Associate Editor for this Diagnostic Exercise:** Ingeborg Langohr

**Editor-in-chief:** Claudio Barros

The Diagnostic Exercises are an initiative of the Latin Comparative Pathology Group (LCPG), the Latin American subdivision of The Davis-Thompson Foundation. These exercises are contributed by members and non-members from any country of residence. Consider submitting an exercise! A final document containing this material with answers and a brief discussion will be posted on the CL Davis website (<https://davisthompsonfoundation.org/diagnostic-exercise/>)