



# Diagnostic Exercise

## From the CL Davis/SW Thompson Foundation

Case #: **231**; Month: **February**; Year: **2024**

*Answer Sheet*

**Title:** Canine alopecia X-Like disorder

**Contributors:** Megan Crawford<sup>1</sup>, Annette Lundberg<sup>2</sup>, and Rachel Neto<sup>3</sup>

<sup>1</sup>College of Veterinary Medicine, Michigan State University, East Lansing MI, USA

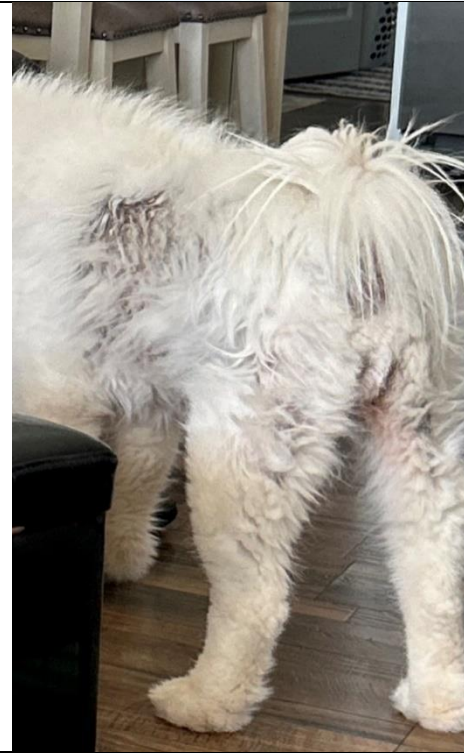
<sup>2</sup>Department of Clinical Sciences, Auburn University, Auburn AL, USA.

<sup>3</sup>Department of Pathobiology, Auburn University, Auburn AL, USA.

\***Corresponding author:** [rtn0004@auburn.edu](mailto:rtn0004@auburn.edu)

**Clinical History:** A 6-year-old spayed female Samoyed dog was presented to the Dermatology Service at Auburn University Veterinary Teaching Hospital (AUVTH) for a 6-month history of non-pruritic alopecia on the hips and back, with the skin turning black in those areas (Figures 1 and 2). The animal had a prior history of hypothyroidism (controlled at the time of evaluation) and a urinary tract infection. The dog was on levothyroxine, Interceptor plus, Nexgard, fish oil, and Royal Canin Veterinary Diet Adult Urinary SO Dry Dog Food. There was no travel history outside the Southern United States. This animal was cohoused with another healthy dog. Bloodwork was unremarkable and testing for Cushing's disease was negative. Skin scrapes, cytology, and dermatophyte and bacterial cultures were negative.

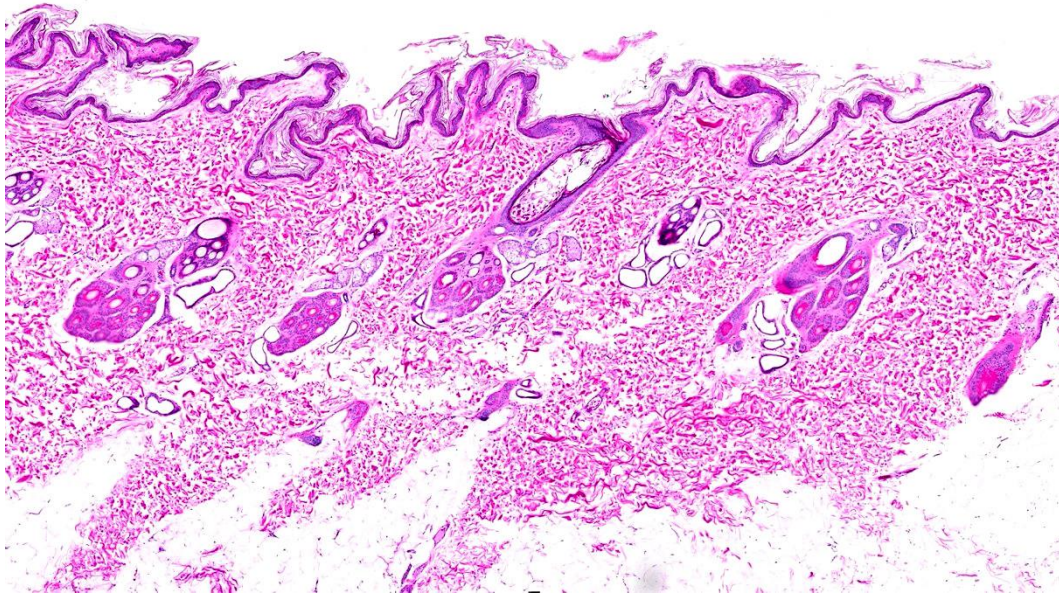
**Gross Findings:** Three 3 x 8 mm punch biopsies from the dorsum are examined. Two of the samples are hyperpigmented and alopecic, alopecic, from the hypotrichotic areas. One of the samples is from the shoulder region with mild hypotrichosis.



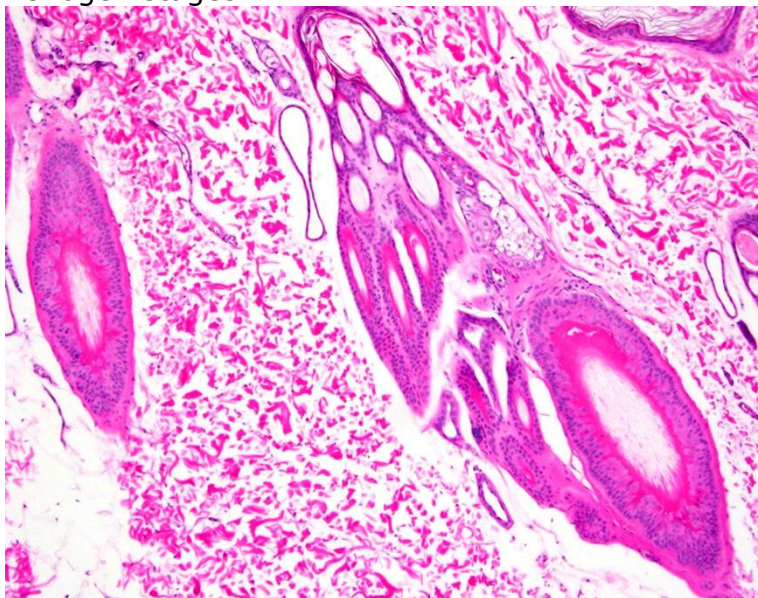
**Figures 1 and 2.** Samoyed dog with patchy regions of alopecia and hyperpigmentation on the lateral trunk and base of the tail / perineal region.

#### **Histopathologic Description:**

Six sections of haired skin punch biopsies from the shoulder and dorsum are examined. In the dorsum, there is moderate atrophy of the epidermis with many stretches of hyperpigmentation and diffuse, moderate, basket-weave to lamellar orthokeratotic hyperkeratosis. The dermis is subjectively thinned when compared to the subcutis. Hair follicles are predominately small and in telogen and kenogen (hairless telogen) stages, with bright eosinophilic smudgy to vitreous keratin irregularly anchored to the follicular wall (flame follicles). In these sections, hair follicles in anagen stage are rare to absent. Sebaceous and sweat glands are unremarkable. In the two sections from the shoulder, there are similar changes, but a few hair follicles are in anagen stage.



**Figure 3.** Haired skin. The epidermis contains stretches of moderate orthokeratotic hyperkeratosis. Several hair follicles are in the telogen and kenogen stages.



**Figure 4.** Haired skin. Hair follicles contain bright eosinophilic smudgy to vitreous keratin irregularly anchored to the follicular wall, consistent with flame follicles.

#### **Follow-Up Questions:**

*Using the history and clinical photographs, what would be the main differential diagnoses for the lesions shown?*

Clinical differential diagnoses for general noninflammatory alopecia in dogs include but are not limited to follicular dysplasia, color dilution alopecia, pattern alopecia, recurrent flank alopecia, alopecia X, alopecia X-like disorder, canine traction alopecia, alopecia areata, pseudopelade, hypothyroidism, hyperadrenocorticism, hyperestrogenism.



Of all the listed conditions, alopecia X-like disorder was the most likely differential diagnosis based on the signalment, history, and clinical pictures. In this case, endocrinopathies were ruled out by clinical work-up.

*Based on the photomicrographs, what is your morphologic diagnosis?*

Hair cycle arrest (telogen and kenogen) with flame follicles, epidermal atrophy, hyperpigmentation and orthokeratotic hyperkeratosis.

*Cause?*

Noninflammatory alopecia, with Alopecia X-like disorder being the most likely differential diagnosis based on the clinical description.

**Discussion:** Alopecia X has many names, including adrenal sex hormone alopecia, castration responsive dermatosis, Wolly Syndrome, Coat Funk, Black Skin Disease, Pseudocushings, and growth hormone responsive dermatosis.(2) Characterized by noninflammatory non-pruritic hair loss with hyperpigmentation, this condition is recognized in breeds with a dense undercoat.(3) Traditionally, breeds associated with alopecia X include, but are not limited to, Samoyed, Pomeranian, Chow Chow, Alaskan Malamute, and Poodle.(3) However, in a recently published comprehensive review of canine noninflammatory alopecia, the author stresses that the condition has been predominantly studied on Pomeranian dogs and that the conventional term "Alopecia X" should be reserved for patients of this or closely related breeds (German and Italian spitz) given the greater likelihood of hereditary factors. In other genetically distant breeds, the term "alopecia X-like disorder" is suggested. (4) Abnormal hormonal metabolism is thought to play a role in the disease, but this remains under investigation. (3) The alopecia will often develop at 1 to 2 years of age. (2)

Clinical signs of alopecia X include symmetrical non-pruritic alopecia and hyperpigmentation of the trunk, caudal thighs, and neck without any systemic signs.(3) The head and distal extremities will be spared from alopecia.(2) Differential diagnoses for alopecia X and alopecia X-like disease include hypothyroidism, hyperadrenocorticism, sex hormone endocrinopathies, follicular dysplasia, recurrent flank alopecia, and telogen or anagen defluxion.(3) The differential diagnoses can be narrowed down by history, physical exam findings, blood work, endocrinopathy testing, skin scraping with cytology, and skin biopsies.

Alopecia X or alopecia X-like disorder is a diagnosis of exclusion. Histologically, the main lesions include many telogen and kenogen stages with trichilemmal keratinization ("flame follicles"), some atrophic hair follicles, as well as variable follicular keratosis and epidermal hyperpigmentation.(3,4) Alopecia X is purely a cosmetic disease, and overall health will not be impaired.(3) While more research is needed in regard to treatment, melatonin is a hormone supplement used to help stimulate hair growth in ~40% of affected dogs within 3 to 4 months of starting treatment.(1)

In this case, the dog was started on melatonin 3mg tablets. At three months post-treatment, her hair coat had subtle improvement per clinical

examination, whereas the owner and groomer made positive comments about fur regrowth on the affected areas.

**References:**

1. Frank LA, Donnell RL, Kania SA. Oestrogen receptor evaluation in Pomeranian dogs with hair cycle arrest (alopecia X) on melatonin supplementation. *Veterinary Dermatology* 2006;17: 252-8.
2. Hargis AM, Myers S. The Integument. In: Zachari FF, editor. *Pathologic Basis of Veterinary Disease*. 6<sup>th</sup> ed. Missouri: Elsevier; 2017. p. 1136.
3. Heinrich NA, Eisenschenk M, Harvey RG, Nuttall T. Alopecic dermatoses. In: *Skin Diseases of the Dog and Cat*. 3rd ed. Florida: CRC Press.; 2019; p. 95-7.
4. Welle MM. Canine noninflammatory alopecia: An approach to its classification and a diagnostic aid. *Vet Pathol*. 2023;60(6):748-69.

\*The Diagnostic Exercises are an initiative of the Latin Comparative Pathology Group (LCPG), the Latin American subdivision of The Davis-Thompson Foundation (DTF). These exercises are contributed by members and non-members from any country of residence. Consider submitting an exercise! A final document containing this material with answers and a brief discussion will be posted on the DTF website

(<https://davisthompsonfoundation.org/diagnostic-exercise/>)

**Editor in Chief:** Claudio Barros

**Associate Editor for this Diagnostic Exercise:** Saulo Pavarini