



Diagnostic Exercise

From The Davis-Thompson Foundation*

Case #278; March; Year: 2026

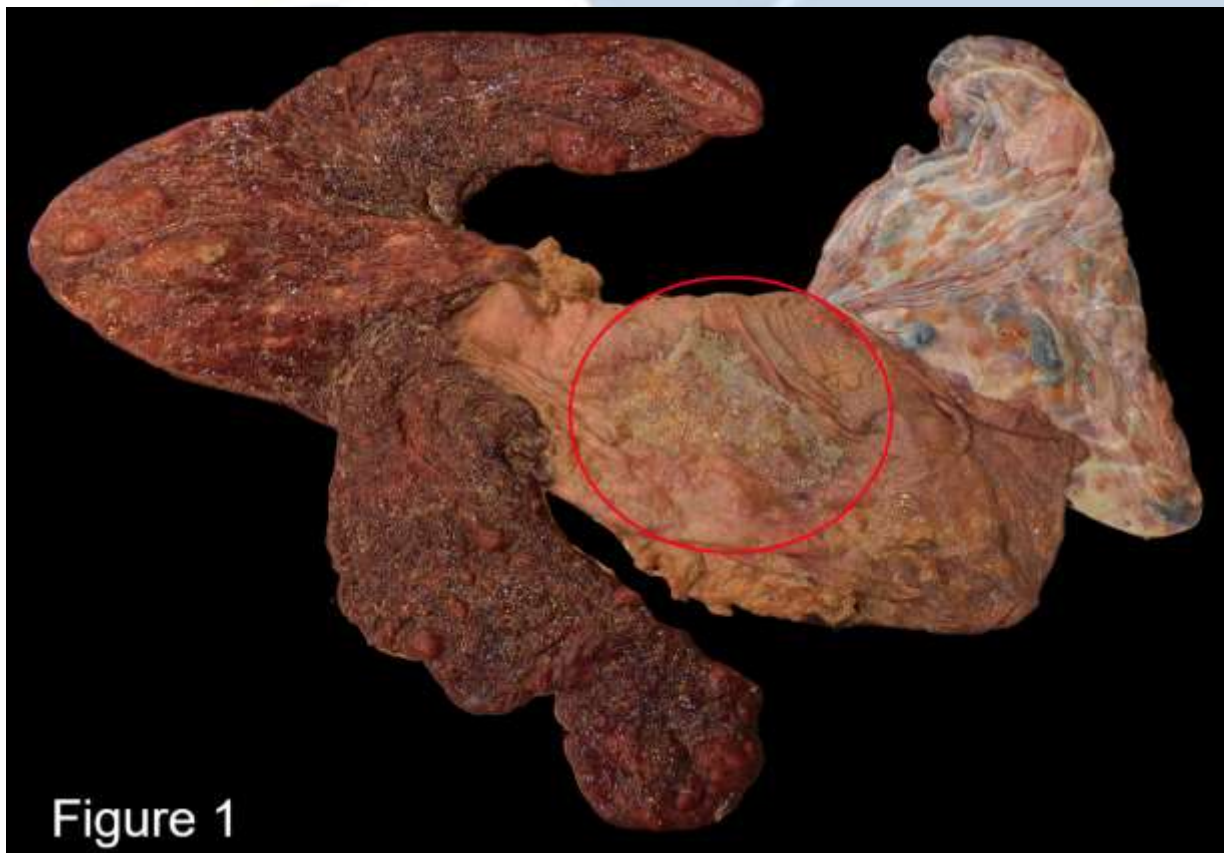
Answer sheet

Title: Equine Nocardioform Placentitis

Contributors: Cassandra M. Powers. California Animal Health and Food Safety Laboratory, Davis, CA and Purdue University, West Lafayette, IN.
cmpowers@ucdavis.edu

History: A placenta from a mare following parturition was submitted for evaluation. The foal was reported to be unusually weak at birth but otherwise grossly normal with no clinical abnormalities. The mare was treated with antibiotics prior to parturition.

Gross Findings: On the surface of the center of the body of the placenta is a poorly demarcated focal area composed of thick, tan, sticky, brown, mucoid exudate on the avillous region (**Figure 1, red circle**).



Histopathology:

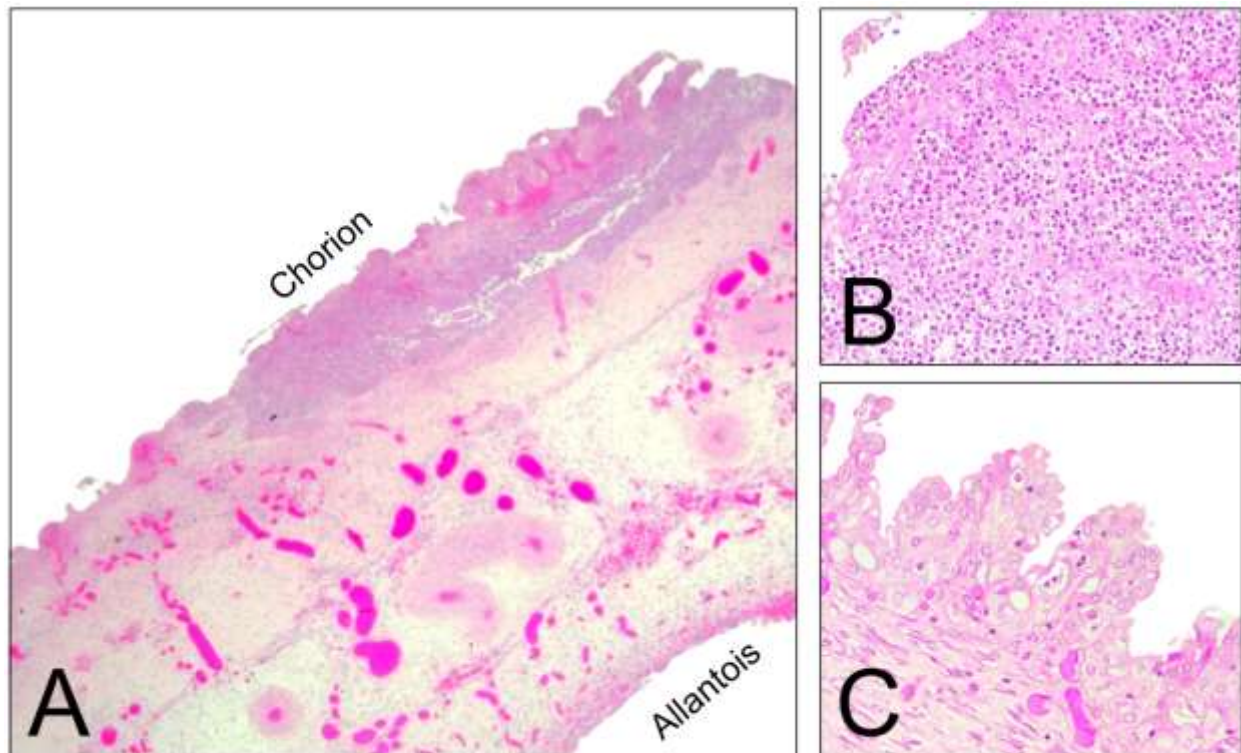


Figure 2

Histologic description:

Placenta: Twelve sections of placental tissue were examined in total. Within five of the sections taken at the site of the grossly observed mucoid exudate, there is marked inflammation of the chorionic layer (**Figure 2A**). The chorionic epithelium is effaced by marked amounts of eosinophilic necrotic material, eosinophilic serous fluid, eosinophilic fibrillar material (fibrin), and numerous degenerate neutrophils (**Figure 2B**). There is mild to moderate multifocal allantoic adenomatous hyperplasia on the apposing allantoic surface (**Figure 2C**). The adenomatous hyperplasia was composed of hyperplastic allantoic epithelium that was forming pseudoglands filled with neutrophils and proteinaceous fluid. Coalescing pseudoglands of various sizes were markedly expanding the allantoic stroma. Within the remaining section are blunted and fused villi within the chorion. The stroma of the chorioallantois is expanded by clear with low numbers of lymphocytes and macrophages. The remaining chorioallantois, amnion, and umbilical cord had mild to moderate diffuse congestion.

Morphologic diagnosis:

1. Placenta: Focal mucoid placentitis

2. Placenta, chorion: Marked acute diffuse suppurative chorionitis with villar blunting and fusion
3. Placenta, allantois: Adenomatous hyperplasia
4. Placenta, chorioallantois: Mild lymphohistiocytic vasculitis and congestion

Etiology: *Amycolatopsis* spp, *Crosiella equi*, *Streptomyces* spp., or *Nocardia* spp.

Name the disease: Nocardioform Placentitis (NP)

Comments:

Nocardioform placentitis is a leading cause of reproductive losses in horses bred in central Kentucky and has been reported in Europe, South Africa, and South America (2, 3). The horse from this case came from southern Indiana, close to the northern border of Kentucky. It is a disease in pregnant mares that can lead to placental insufficiency and late-term abortions, stillbirths, or weak foals. The infection does not always cause immediate fetal damage. Instead, it leads to placental insufficiency, where the placenta can no longer adequately support the fetus, which can result in a low-birth-weight foal or abortion (1, 4).

Prior to foaling or abortion, mares with nocardioform placentitis may have premature mammary gland development but will not have vulvar discharge. An ultrasound may reveal large areas of separation between the chorion and the endometrium, filled with fluid (4).

This disease is associated with gram positive actinomyces, including *Amycolatopsis* spp, *Crosiella equi*, *Streptomyces* spp., and *Nocardia* spp. (1, 4, 5). Coinfection with multiple organisms is rare but reported. While they were once thought to be fungi, actinomycetes are bacteria characterized by their filamentous, branching structure that resembles fungal hyphae (4, 5).

Placentas from mares with nocardioform placentitis, classically have a loss of chorionic microvilli in a focal area of the placenta associated with the base of the uterine horns. The disease is characterized by distinctive lesions on the chorionic surface of the placenta, which are often covered in a thick, tan, mucoid exudate with a characteristic odor. The affected section of the placenta is often thickened, and can be roughened or have a reddish-white, mottled appearance underneath the exudate (1). Adjacent villi may be thickened and edematous. The allantoic surface may show rounded projections or cystic formations, adenomatous hyperplasia. The amnion and umbilical cord usually appear normal.

Histopathology of nocardioform placentitis shows an avillic chronic lesion in the center with active inflammation, numerous bacteria, and a mucoid exudate containing sloughed cells and leukocytes on the periphery (1, 3). Bacteria was absent in this case due to prior treatment. The chorionic epithelium shows

hyperplasia and degeneration, and the chorionic villi may be blunted or atrophied. Macrophages, lymphocytes, and plasma cells are the main inflammatory cells, often with the presence of gram-positive actinomycetes (3, 4).

While the bacteria are the main suspects, the exact transmission routes are not yet fully understood. Nocardioform organisms are soil-borne and cosmopolitan in distribution (4). Reportedly, various nocardioform organisms have been detected in the soil in other countries, although the pathogenicity of most of these organisms has not been determined. Additionally, there is a reported strong association between weather conditions and an increased occurrence of nocardioform placentitis. Exposure to low rainfall and high temperatures during August and September in central Kentucky when most mares are in mid-gestation results in an increased incidence of abortion later in pregnancy (4).

References:

1. Bailey, S., Leite, T., & Troedsson, M. (2024). Reproductive and health outcomes of horses affected by focal mucoid placentitis. *Clinical Theriogenology*, 16.
2. Carneiro, F. P., Alonso, M. A., Redoan, M. A., Henriques, D. A., Lima, F. M., Oliveira, R. M., ... & Fernandes, C. B. (2022). First confirmed diagnosis of nocardioform placentitis (*Amycolatopsis lexingtonensis*) in South America. *Journal of Equine Veterinary Science*, 110, 103835.
3. Christensen, B. W., Roberts, J. F., Pozor, M. A., Giguere, S., Sells, S. F., & Donahue, J. M. (2006). Nocardioform placentitis with isolation of *Amycolatopsis* spp in a Florida-bred mare. *Journal of the American Veterinary Medical Association*, 228(8), 1234-1239. Retrieved Oct 23, 2025, from <https://doi.org/10.2460/javma.228.8.1234>
4. Fedorka, C. E., Scoggin, K. E., Ruby, R. E., Erol, E., & Ball, B. A. (2021). Clinical, pathologic, and epidemiologic features of nocardioform placentitis in the mare. *Theriogenology*, 171, 155-161.
5. Ruby, R. E., & Janes, J. G. (2023). Infectious causes of equine Placentitis and Abortion. *Veterinary Clinics: Equine Practice*, 39(1), 73-88.

*The Diagnostic Exercises are an initiative of the Latin Comparative Pathology Group (LCPG), the Latin American subdivision of The Davis-Thompson Foundation (DTF). These exercises are contributed by members and non-members from any country of residence. Consider submitting an exercise! A final document containing this material with answers and a brief discussion will be posted on the DTF website.

(<https://davisthompsonfoundation.org/diagnostic-exercise/>)

Associate Editor for this Diagnostic Exercise: **Franklin-Riet-Correa**
Editor-in-chief: **Claudio Barros**