



# Diagnostic Exercise

## From The Davis-Thompson Foundation\*

Case #259; Month: **April**; Year: **2005**

### *Question sheet*

**Contributors:** Erin Schwalbe, Matias Dorsch, and Jose Cesar Menk\*.

Department of Pathobiological Sciences and Louisiana Animal Disease Diagnostic Laboratory, Louisiana State University School of Veterinary Medicine, Baton Rouge, LA.

\***Corresponding author:** [cmenk2@lsu.edu](mailto:cmenk2@lsu.edu)

**History:** A 3-year-old, female, Plott hound dog had a history of severe fascial pruritus, swelling, and drooling. The week prior, this dog and three other dog hunted feral hogs. At the time this dog was submitted for necropsy at the Louisiana Animal Disease Diagnostics Laboratory (LSU Diagnostics), the two other dogs had already died.

**Necropsy findings:** On the left frontal and temporal regions of the head and extending down to the maxillary region, there were coalescing alopecic, dark red, irregular areas measuring up to 12 x 5 cm (Fig. 1). The subcutis within these regions and adjacent areas including the left submandibular and ventral cervical regions was expanded by edema and hemorrhage. The tonsils were mildly enlarged.

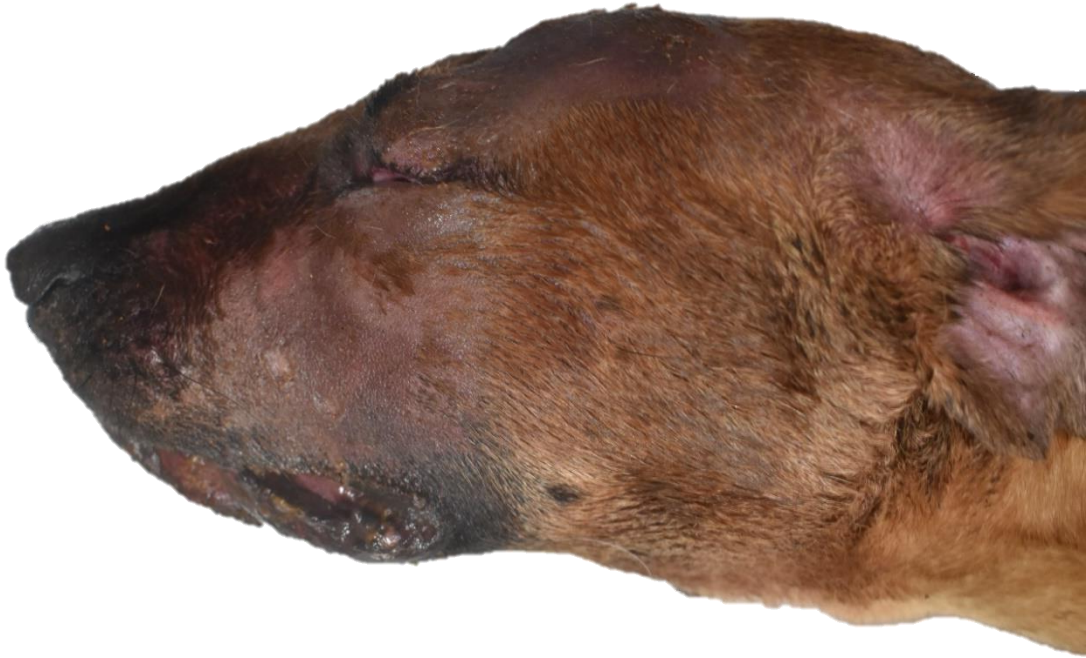

Figure 1

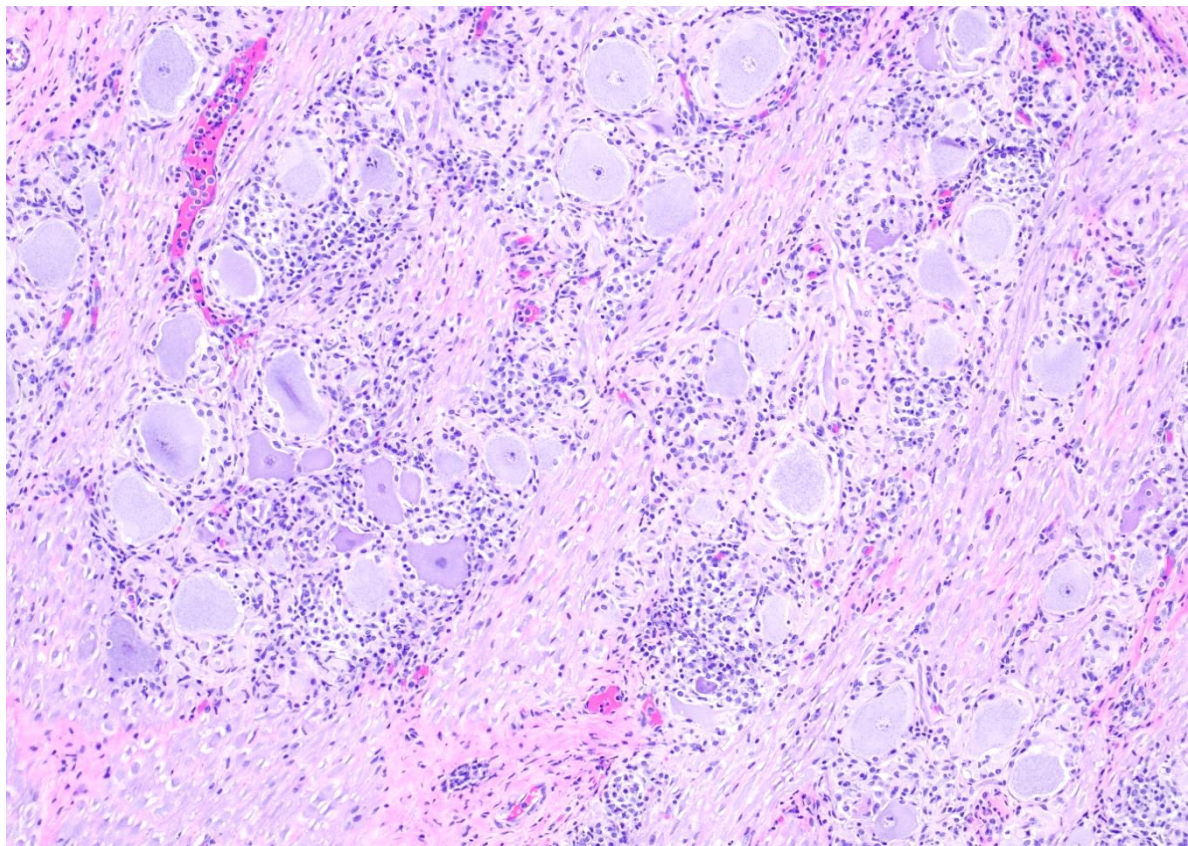


Figure 2: Trigeminal ganglion.

Follow-up questions:

- *Morphologic diagnosis:*
- *Etiology:*
- *Name the disease:*

\*The Diagnostic Exercises are an initiative of the Latin Comparative Pathology Group (LCPG), the Latin American subdivision of The Davis-Thompson Foundation (DTF). These exercises are contributed by members and non-members from any country of residence. Consider submitting an exercise! A final document containing this material with answers and a brief discussion will be posted on the DTF website.

(<https://davisthompsonfoundation.org/diagnostic-exercise/>)

**Associate Editor for this Diagnostic Exercise:** Daniel Rissi  
**Editor-in-chief:** Claudio Barros