



Diagnostic Exercise From The Davis-Thompson Foundation*

Case #: **154** Month: **November** Year: **2020**

Contributors: Tsukasa Sakashita,¹ DVM Student; Mariano Carossino,² DVM, PhD, DACVM; Ingeborg M. Langohr,² DVM, MS, PhD, DACVP; Clare Scully,³ DVM, MS, DACT; Nobuko Wakamatsu-Utsuki,² DVM, PhD, DACPV, DACVP

¹Department of Veterinary Pathology, Faculty of Agriculture, University of Miyazaki, Miyazaki, Japan

²Louisiana Animal Diagnostic Disease Laboratory (LADDL) and Department of Pathobiological Sciences, School of Veterinary Medicine, Louisiana State University, Baton Rouge, LA, USA.

³Department of Veterinary Clinical Sciences, School of Veterinary Medicine, Louisiana State University, Baton Rouge, LA, USA.

Clinical History: 6-year-old, female Boer goat. The animal presented to the LSU Veterinary Teaching Hospital with lethargy, abdominal distension, and diarrhea. Physical exam revealed a fluid wave and chemosis. Due to the severity of her condition, humane euthanasia was elected.

Necropsy Findings: The serosa of the small intestine had multifocal, white, 2 to 4 mm, firm nodules. The mucosa of the ileum was multifocally thickened with prominent yellow to pale pink mucosal folds. The mesenteric lymph nodes were enlarged 2-3 times and firm. The peritoneal cavity contained approximately 6 L of clear, yellow fluid with occasional clear, flocculent material. Other findings included focally extensive necrotizing rumenitis and fibrinous peritonitis, lymphoplasmacytic abomasitis, bronchopneumonia, and tracheobronchial lymphadenomegaly.

Gross and Microscopic Images:

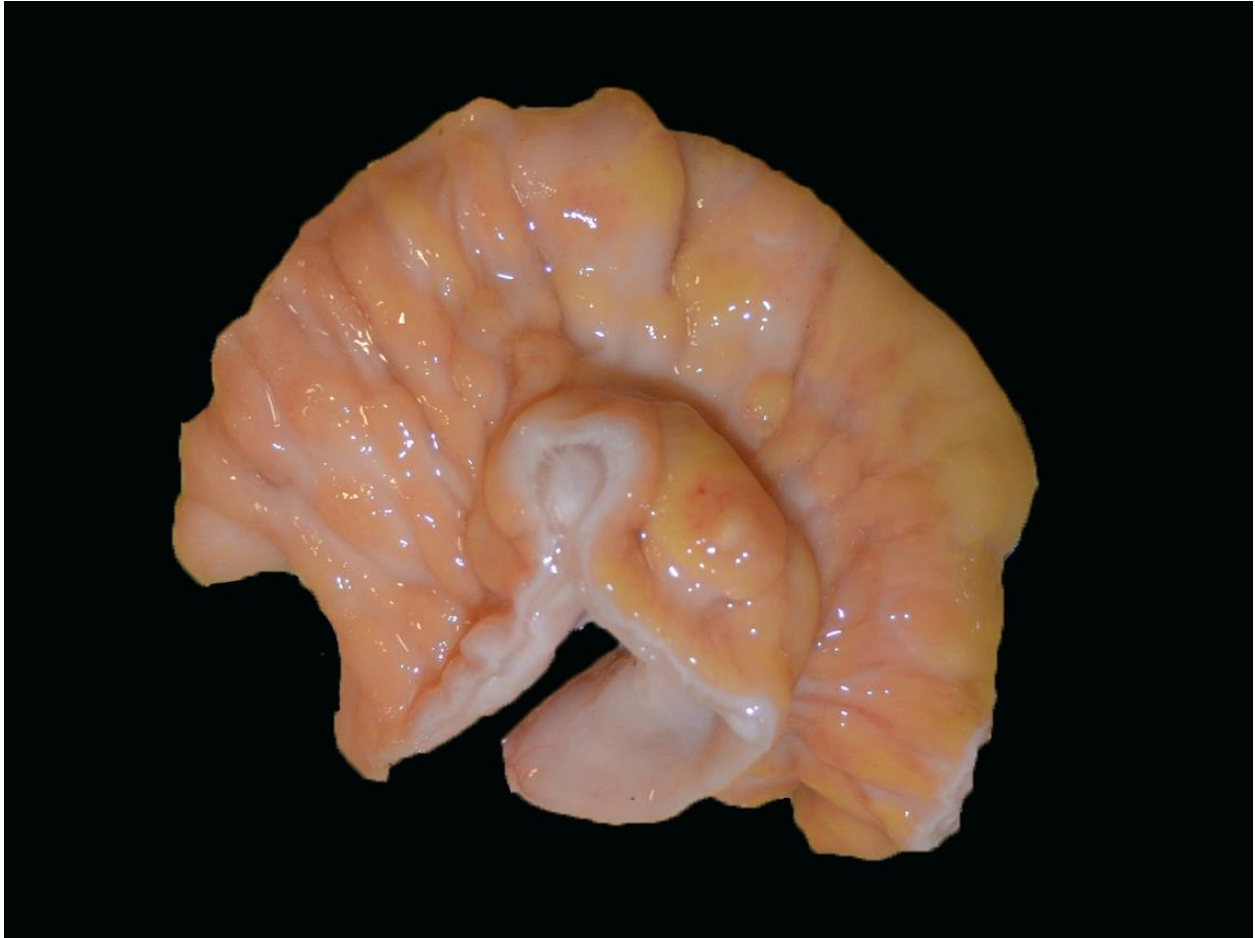


Figure 1. Small intestine, mucosal surface.

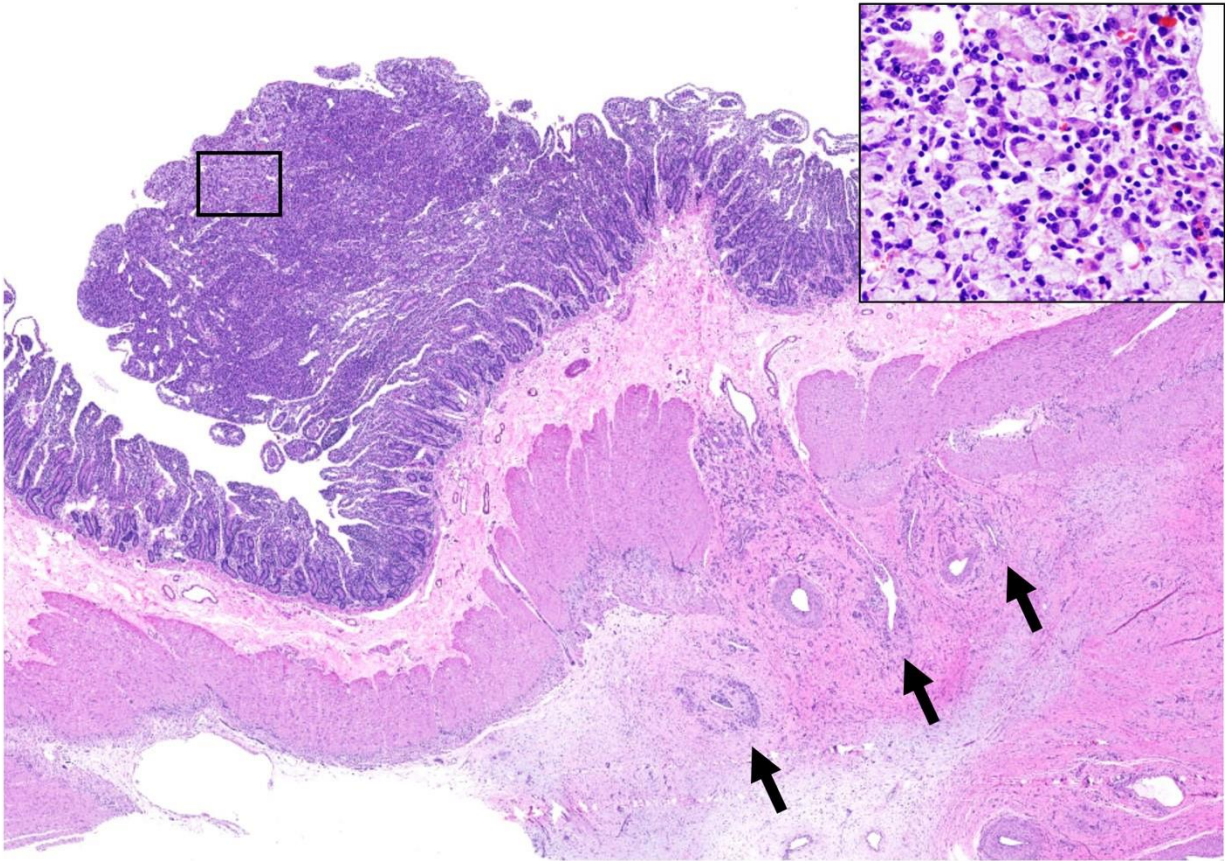


Figure 2. Small intestine. Hematoxylin and eosin; 1.25X and 20X (inset).

Follow-up questions:

- 1) Microscopic description
- 2) Morphologic diagnosis

*The Diagnostic Exercises are an initiative of the **Latin Comparative Pathology Group (LCPG)**, the Latin American subdivision of The Davis-Thompson Foundation. These exercises are contributed by members and non-members from any country of residence. Consider submitting an exercise! A final document containing this material with answers and a brief discussion will be posted on the CL Davis website (http://www.cldavis.org/diagnostic_exercises.html).

Associate Editor for this Diagnostic Exercise: Mariano Carossino

Editor-in-chief: Claudio Barros