

# Diagnostic Exercise

## From The Davis-Thompson Foundation\*

Case #254; Month: February; Year: 2025

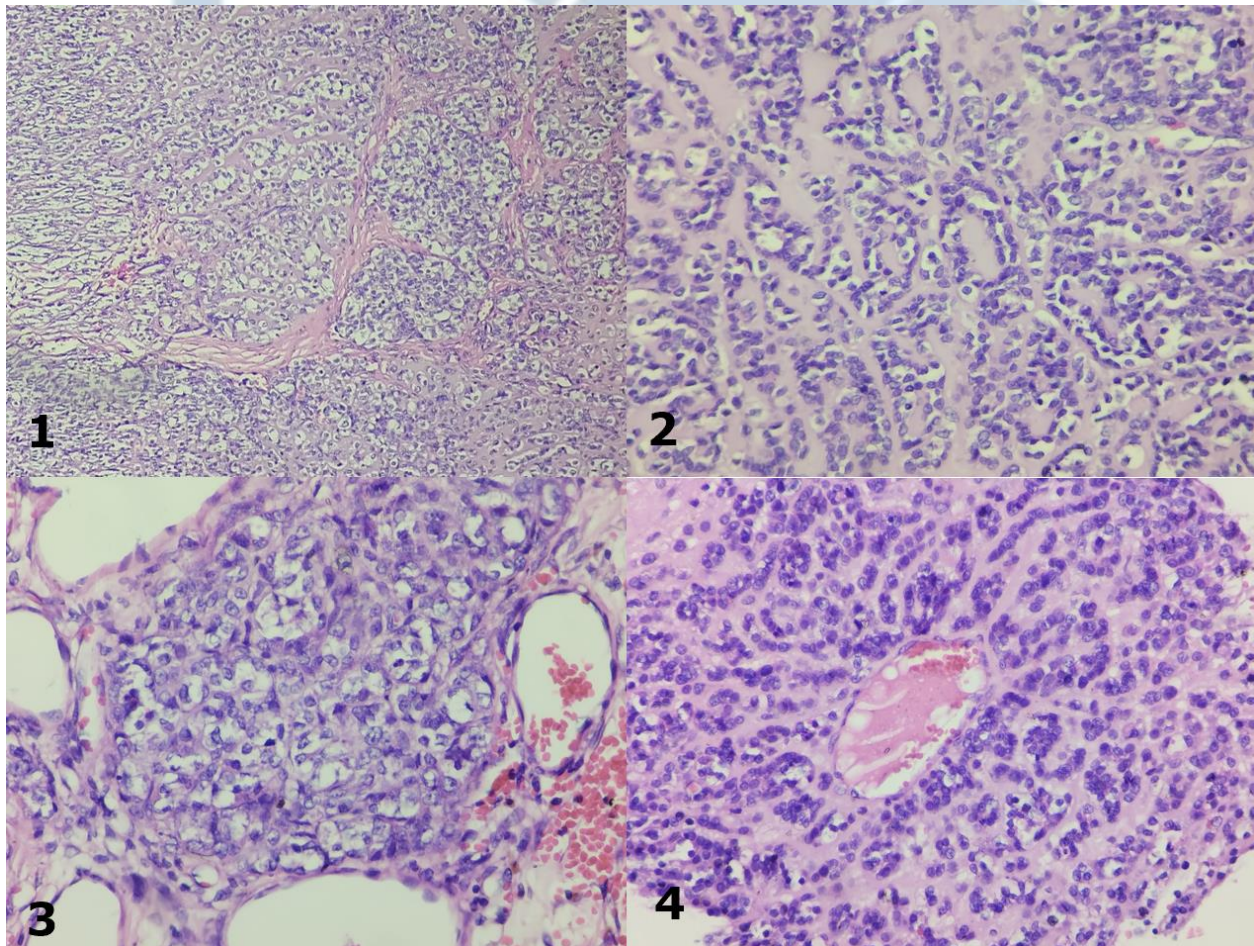
### Question sheet

**Contributors:** Renata Brizzio<sup>1</sup>, Cecilia Degiovanni<sup>1</sup>, Ana Maria Martin<sup>1</sup>.

<sup>1</sup>Patologia Animal Cordoba, Cordoba, Argentina.

**Corresponding author:** E-mail: [cecidegiovanni28@gmail.com](mailto:cecidegiovanni28@gmail.com)

**History:** An 8-year-old female mixed-breed dog with pericardial effusion was diagnosed with a tumor at the base of the heart. Grossly, the mass was firm, white, and irregular. A sample of the mass (Figs. 1-4) was submitted to histopathology.



Follow-up questions:

- *Morphologic diagnosis:*
- *Differential diagnosis:*

\*The Diagnostic Exercises are an initiative of the Latin Comparative Pathology Group (LCPG), the Latin American subdivision of The Davis-Thompson Foundation (DTF). These exercises are contributed by members and non-members from any country of residence. Consider submitting an exercise! A final document containing this material with answers and a brief discussion will be posted on the DTF website.

(<https://davisthompsonfoundation.org/diagnostic-exercise/>)

**Associate Editor for this Diagnostic Exercise:** Saulo Pavarini  
**Editor-in-chief:** Claudio Barros