



# Diagnostic Exercise

## From The Davis-Thompson Foundation\*

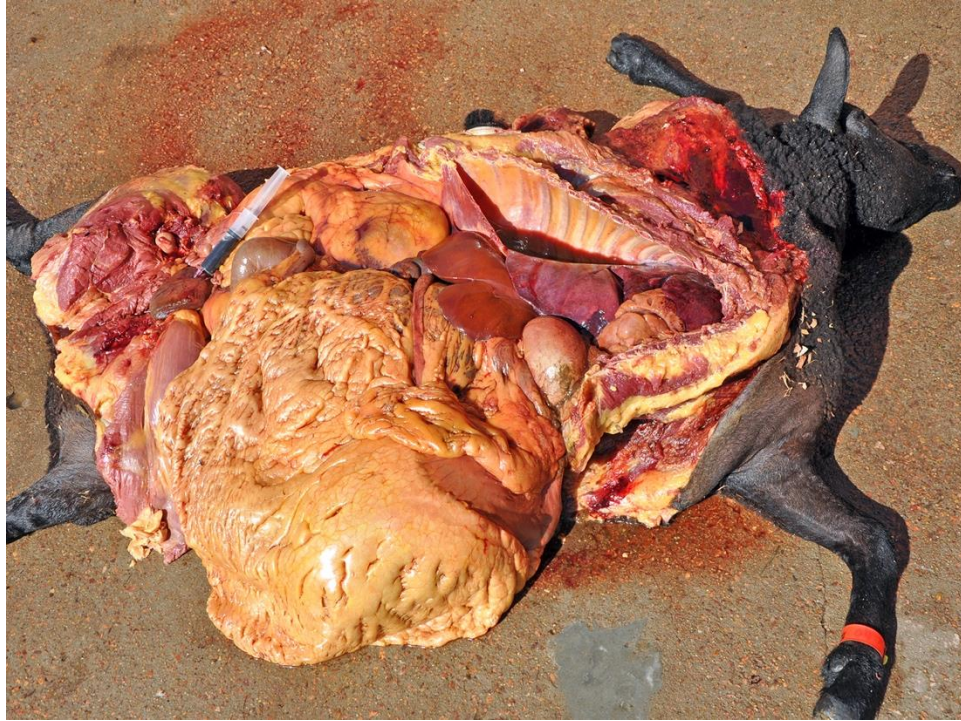Case #: **186**; Month: **April**; Year: **2022**  
*Question Sheet*

**Contributors:** Bianca S. de Cecco, DVM, MSc, Franciéli A. Molossi, DVM, MSc, Lauren S. de Mello, DVM, MSc, Matheus V. Bianchi, DVM, MSc, PhD, Saulo P. Pavarini, DVM, MSc, PhD. Setor de Patologia Veterinária, Faculdade de Medicina Veterinária, Universidade Federal do Rio Grande do Sul (UFRGS), Porto Alegre, RS, Brazil. Corresponding author: Universidade Federal do Rio Grande do Sul. [biasantanacecco@gmail.com](mailto:biasantanacecco@gmail.com)

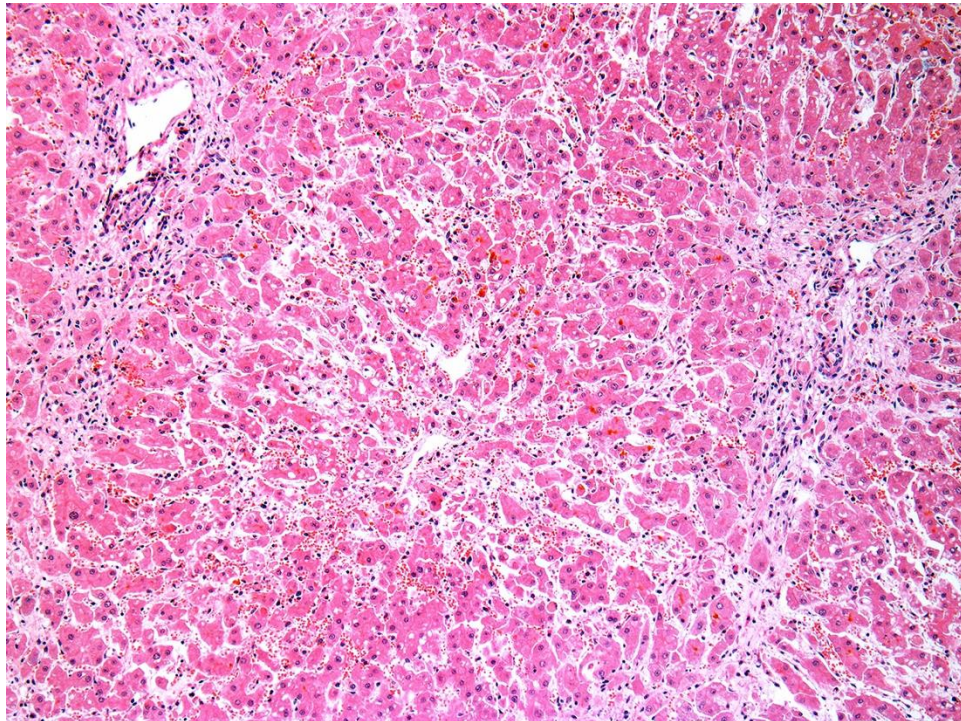
**Clinical History:** A one-year-old female Texel sheep had a one-day history of anorexia and jaundice that progressed to lethargy, lateral recumbency, and death within hours. The sheep was part of a 20 sheep flock, housed indoors, and was receiving an increasing amount of feed, high in grains (specific for sheep) for the last two months, as it was being prepared for a national fair.

**Gross Findings:** The sheep was in very good body condition. The carcass was discolored by marked icterus. In the subcutaneous tissue, there were multifocal petechiae and ecchymoses. The kidneys were diffusely red brown. The urinary bladder was distended and filled with dark red to black urine. The liver was slightly soft (friable) and swollen, with a deep orange color. The gallbladder was distended and filled with dark grumous bile.

**Gross and Histological Images:**

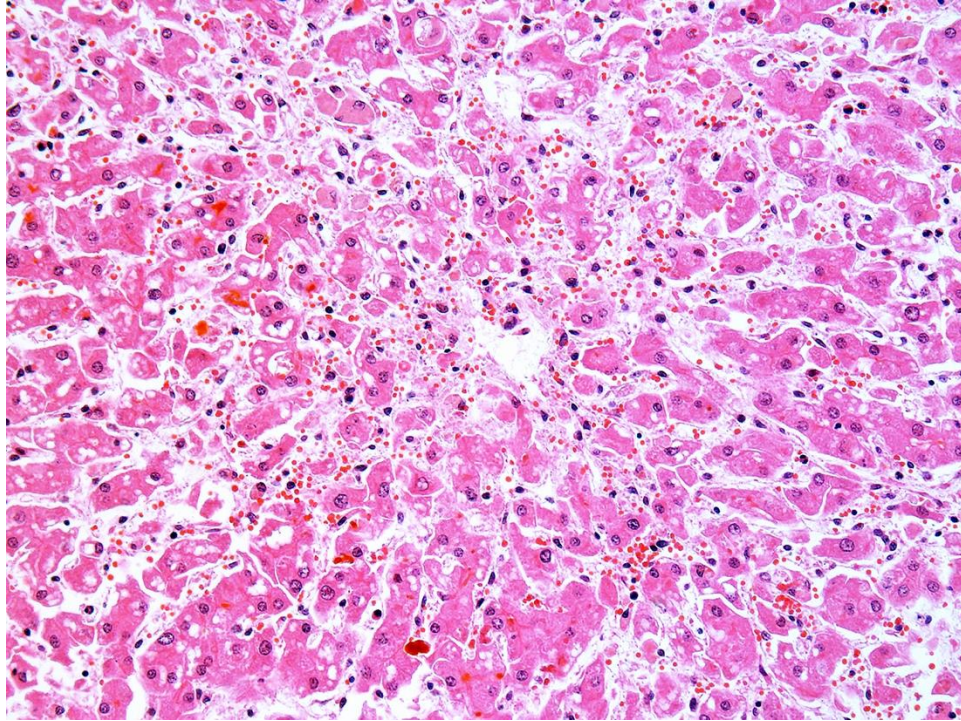


**Figure 1**

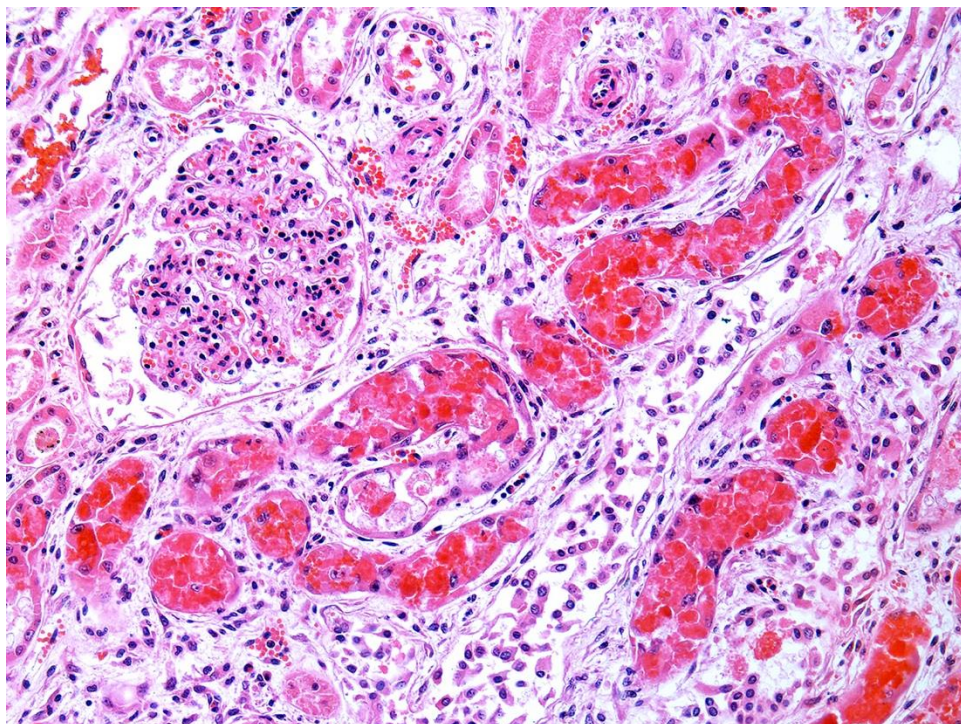


**Figure 2**





**Figure 3**



**Figure 4**

**Follow-up questions:**

- *Cause*
- *Pathogenesis*

\*The Diagnostic Exercises are an initiative of the Latin Comparative Pathology Group (LCPG), the Latin American subdivision of The Davis-Thompson Foundation. These exercises are contributed by members and non-members from any country of residence. Consider submitting an exercise! A final document containing this material with answers and a brief discussion will be posted on the CL Davis website (<https://davisthompsonfoundation.org/diagnostic-exercise/>).

**Editor for this Diagnostic Exercise:** Saulo P. Pavarini

**Editor-in-chief:** Claudio Barros