

# Diagnostic Exercise

## From The Davis-Thompson Foundation\*

Case #: **156** Month: **December** Year: **2020**

**Contributors:** Mirrim Kelly-Bosma BVSc, DVClinSc candidate, Anatomic Pathology Resident, & Associate Professor Rachel Allavena BVSc (hons), BVBIOL, GradDip (Anatomic pathology), GCHEd, MANZCVS, PhD, DACVP. School of Veterinary Science, University of Queensland, Gatton, Australia.

**Clinical History:** 12-day-old Warmblood filly born 5 weeks premature from a mare with placentitis, and treated in the hospital from birth for lung dysmaturity. After a week in intensive care, she developed decubitus ulcers and abscesses, and 2 days later was euthanased due to worsening respiratory signs.

**Necropsy Findings:** There were full thickness skin wounds on the caudal antebrachia just distal to the elbows, which oozed purulent discharge (Figure 1 depicts the worst lesion on the right forelimb). The kidneys (Figure 2) and lungs (Figure 3) had multifocal, round, yellow, soft, well-demarcated nodules that range in size from 5 mm to 30 mm in diameter and that contain pale yellow opaque viscous material on cut surface. There were a few similar smaller lesions, 2-5 mm in diameter, in the myocardium, as well as mild pericardial, pleural, and abdominal effusion with yellow-tinged clear fluid.

**Gross and Microscopic Images:**

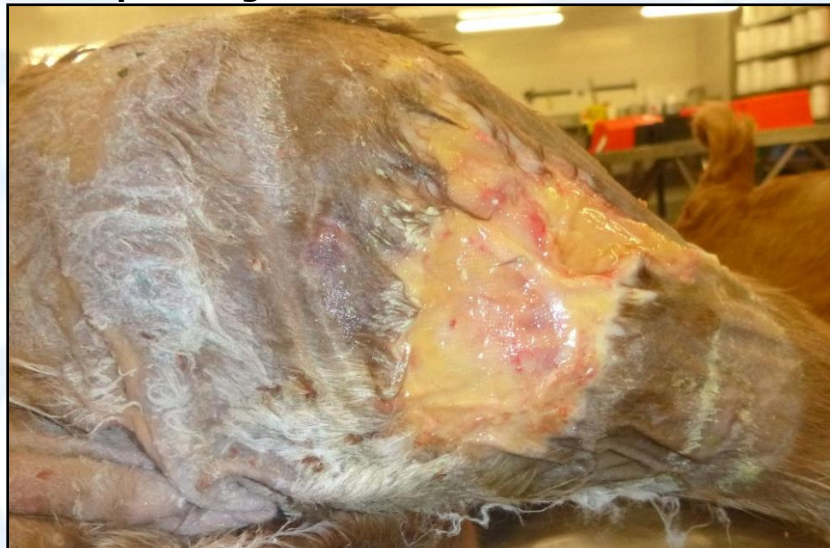

Figure 1: Caudal forelimb

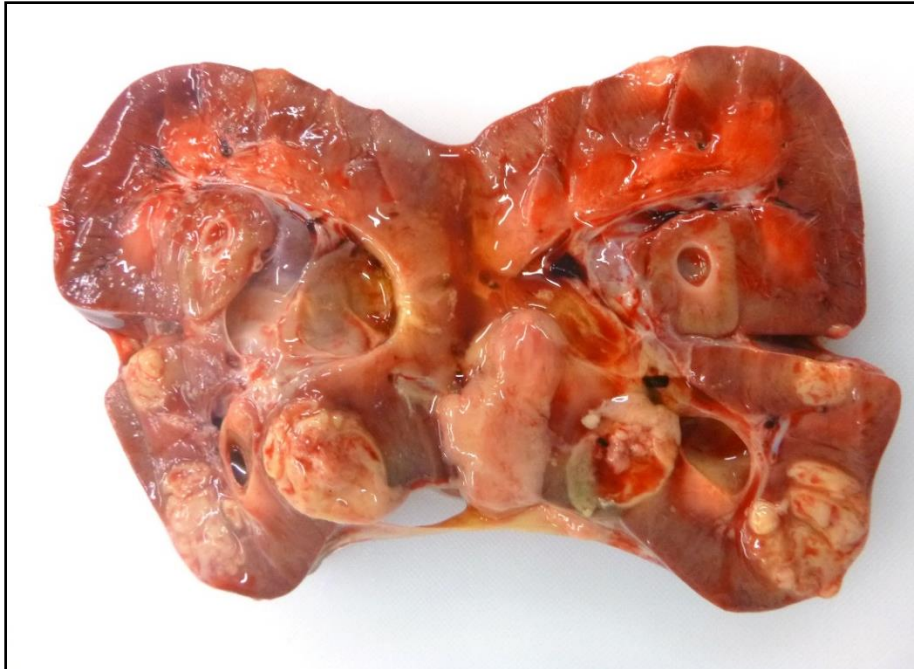

Figure 2

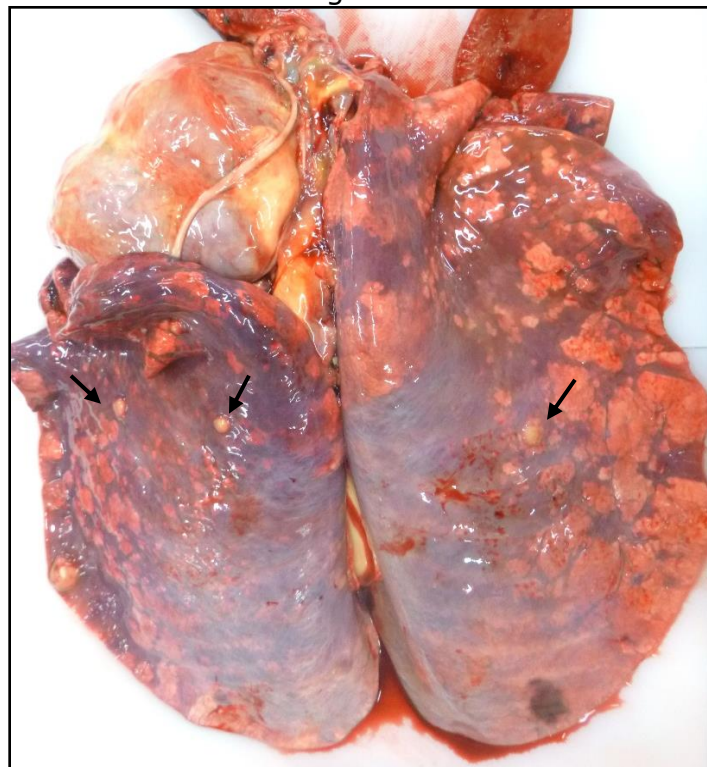


Figure 3



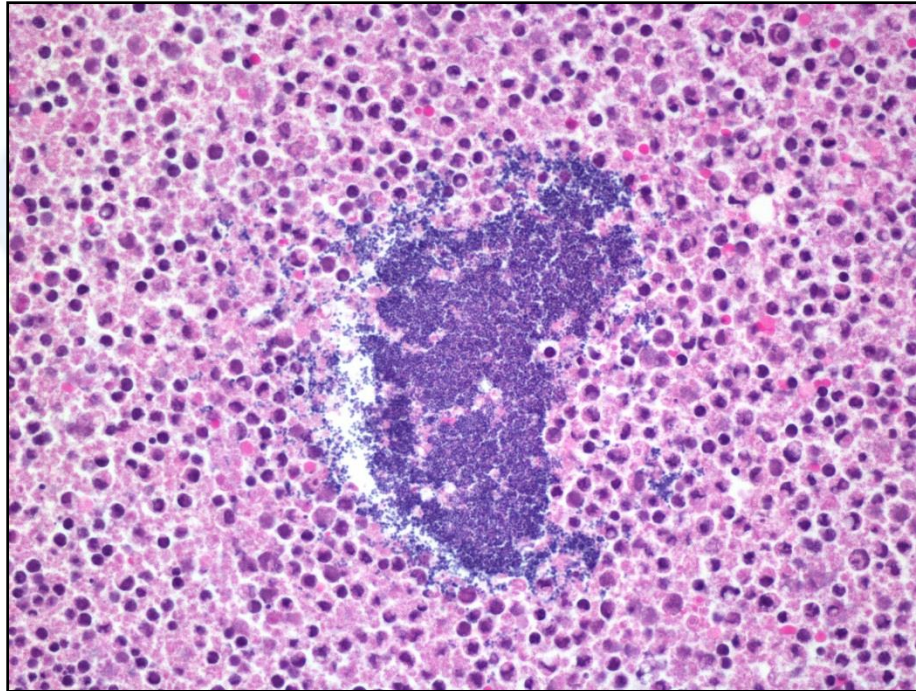


Figure 4

**Follow-up questions:**

- (1) *Morphologic diagnoses*
- (1) *Name one potential cause.*

\*The Diagnostic Exercises are an initiative of the **Latin Comparative Pathology Group (LCPG)**, the Latin American subdivision of The Davis-Thompson Foundation. These exercises are contributed by members and non-members from any country of residence. Consider submitting an exercise! A final document containing this material with answers and a brief discussion will be posted on the CL Davis website ([http://www.cldavis.org/diagnostic\\_exercises.html](http://www.cldavis.org/diagnostic_exercises.html)).

**Associate Editor for this Diagnostic Exercise:** Rachel Allavena

**Editor-in-chief:** Claudio Barros