

DIAGNOSTIC EXERCISE

From The Davis-Thompson Foundation*

Case #274; Month: **December**; Year: **2025**

Question Sheet

Contributors: Althea Wang, Chi Hin Ng, Viviana Gonzalez Astudillo*
The University of Queensland, Veterinary Laboratory Services, School of Veterinary Science, Australia.

***Corresponding author:** v.gonzalez@uq.edu.au

History: A 24-year-old Stockhorse gelding presented for veterinary assessment after developing profuse watery diarrhea. The horse presented with a distended abdomen, decreased gut sounds on both quadrants on the left-hand side, absent gut sounds on the right-hand side and was hypothermic (36.8°C) and heart rate was 44 bpm. The horse was drenched with water, paraffin oil and electrolytes via a nasogastric tube. No net reflux was obtained. Despite administration of pain relief and sedation, the gelding's heart rate continued to increase to 68 bpm. The gelding was transported to a referral service but died upon arrival.

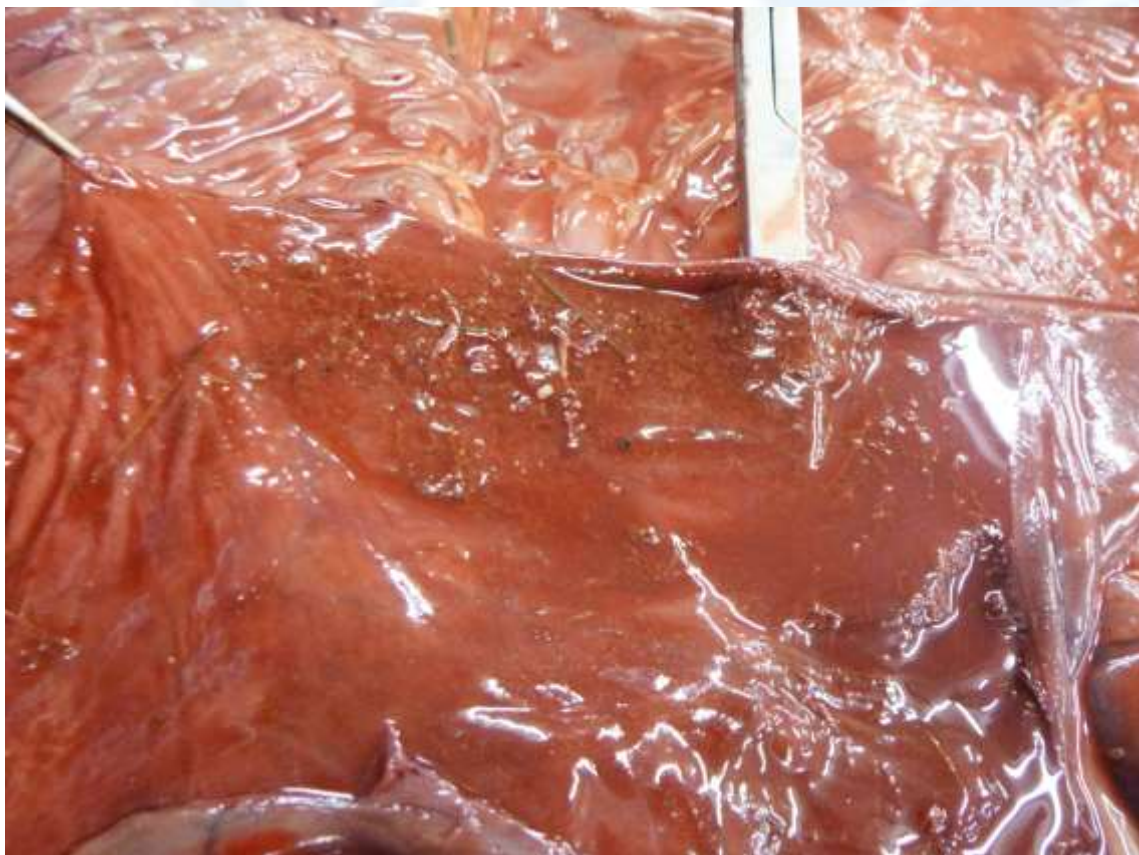

Figure 1. Right dorsal colon.

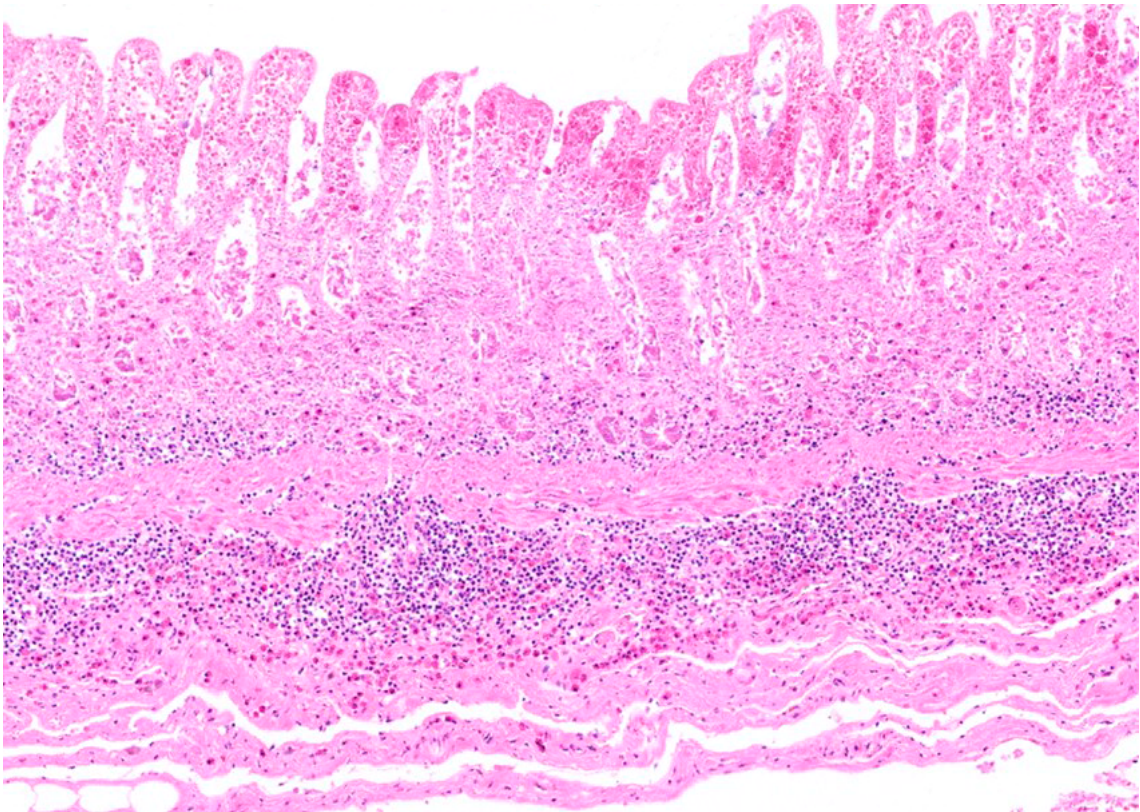


Figure 2. Right dorsal colon, H&E.

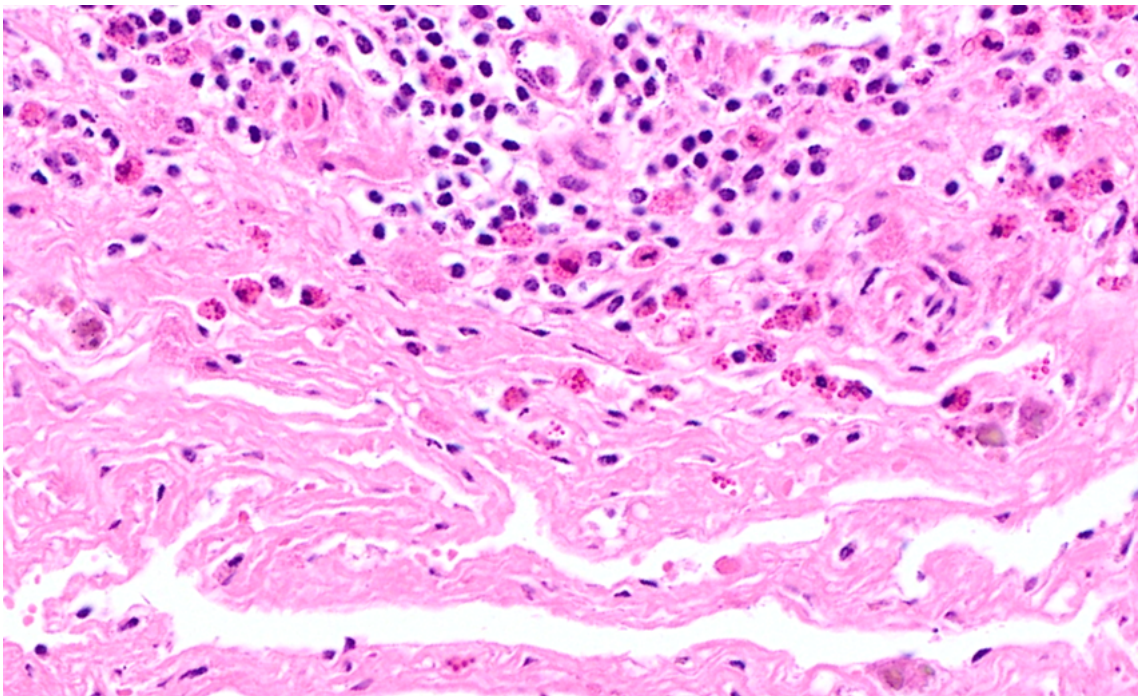


Figure 3. Right dorsal colon, submucosa, H&E.

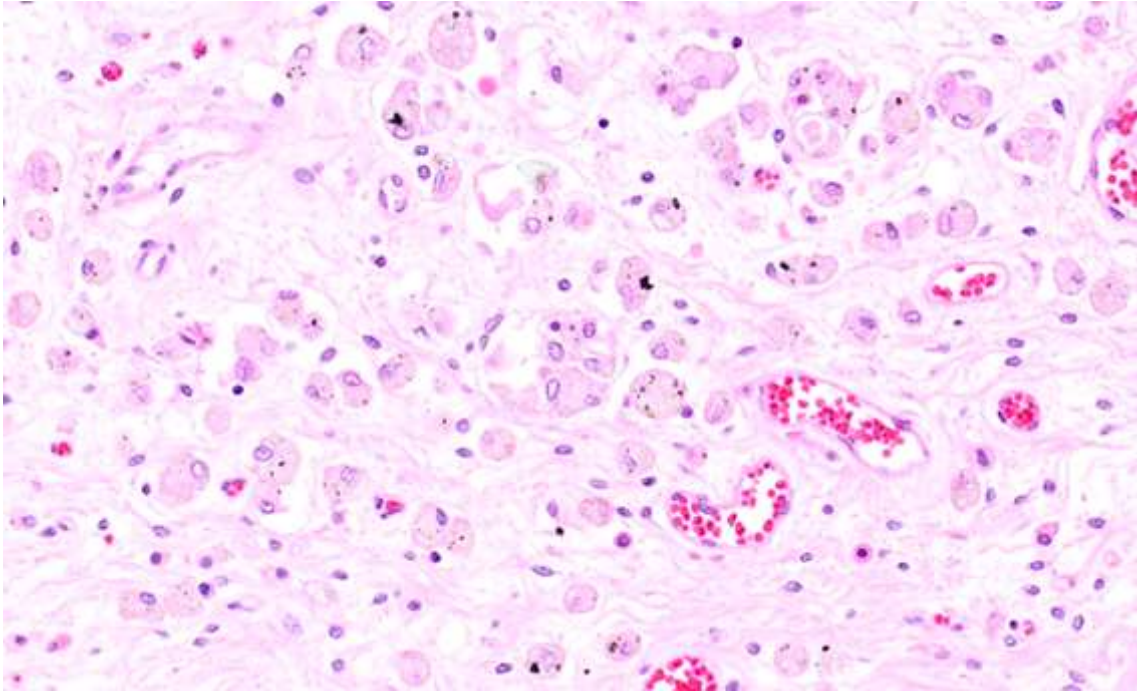


Figure 4. Jejunum, submucosa H&E.

Follow-Up Questions:

- *Gross descriptions*
- *Histopathological descriptions.*
- *Morphologic diagnosis.*
- *Final Diagnosis*

The Diagnostic Exercises are an initiative of the Latin Comparative Pathology Group (LCPG), the Latin American subdivision of The Davis-Thompson Foundation (DTF). These exercises are contributed by members and non-members from any country of residence. Consider submitting an exercise! A final document containing this material with answers and a brief discussion will be posted on the DTF website

(<https://davisthompsonfoundation.org/diagnostic-exercise/>).

Associate Editor for this Diagnostic Exercise: Franklin Riet-Correa
Editor-in-chief: Claudio Barros