

Diagnostic Exercise

From The Davis-Thompson Foundation*

Case: **215**; Month: **June**; Year: **2023**

Question sheet

Contributors: Hodias S. de Oliveira Filho¹, DVM, José L. C. Duarte¹, DVM, Gabriel F. Paranhos¹, DVM, Rafael L. de Oliveira², DVM, MSc, Jeann L. de Araújo¹, DVM, MSc, PhD.

¹Laboratory of Veterinary Pathology, Federal University of Paraíba (UFPB), Areia, PB, Brazil. ²Wild animal clinic sector, Federal University of Paraíba (UFPB), Areia, PB, Brazil. lealjeann@gmail.com

Clinical History: A young male turkey (*Meleagris gallopavo*) was referred to the Veterinary Hospital of the Federal University of Paraíba (UFPB), having multiple skin nodules. The owner reported that twenty-four chickens (twelve adult and twelve young) and nine turkeys (four adult and five young) had similar lesions on the same property. The animals were raised together, and several birds died, mainly turkeys and chicks.

Clinical Findings: The turkey was numb, with multifocal to coalescing firm crusted nodules with a depressed center were on the head, neck and limbs, and focally extensive areas of necrosis in the oral cavity. Fragments from the skin lesions were sampled for biopsy.

Gross Images:

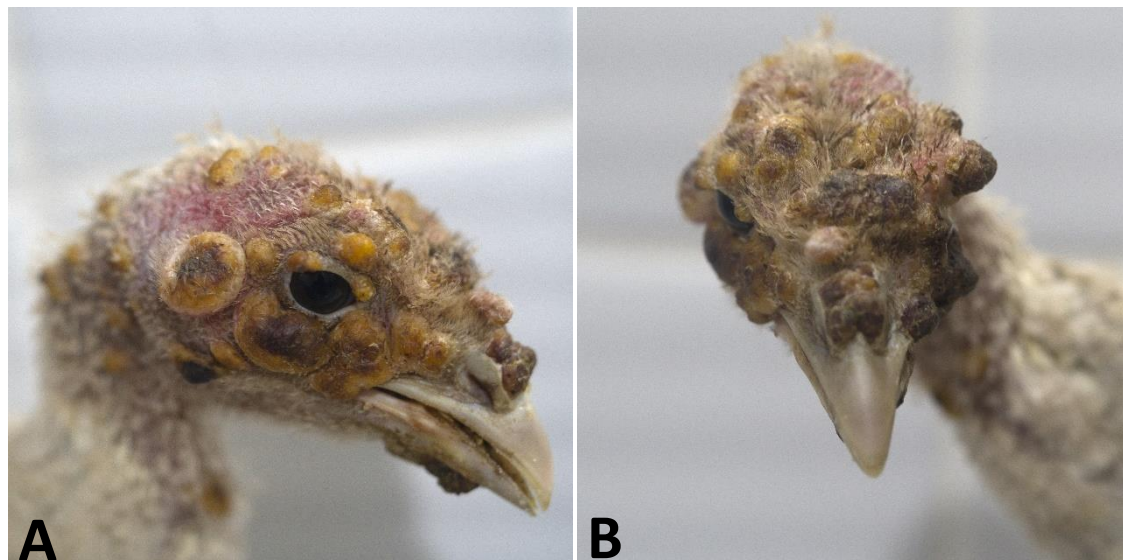


Figure 1

Microscopic Images:

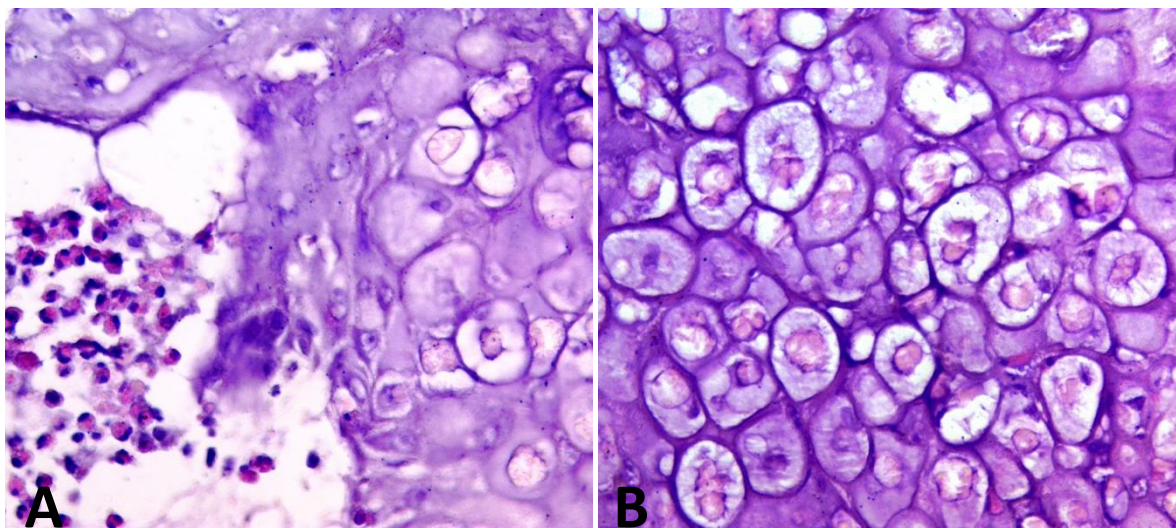


Figure 2

Follow-up questions:

- (1) *Histological description*
- (2) *Name of the condition*
- (3) *Etiology*
- (4) *Forms of clinical presentation*
- (5) *Two differential diagnoses*

Editor-in-chief: Claudio Barros

Associate Editor for this Diagnostic Exercise: Raquel Rech