



Diagnostic Exercise

From The Davis-Thompson Foundation*

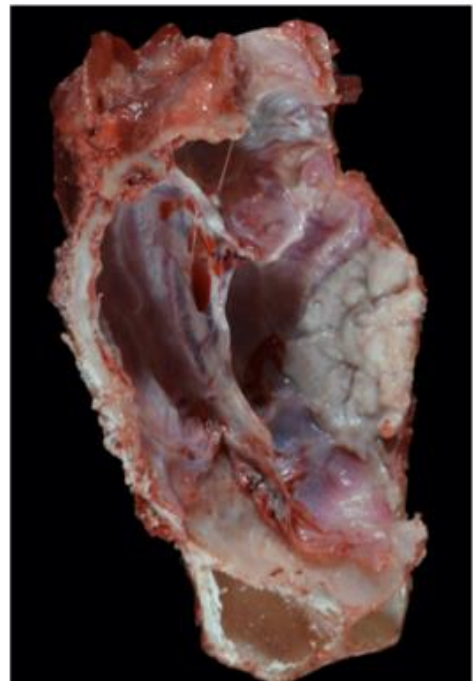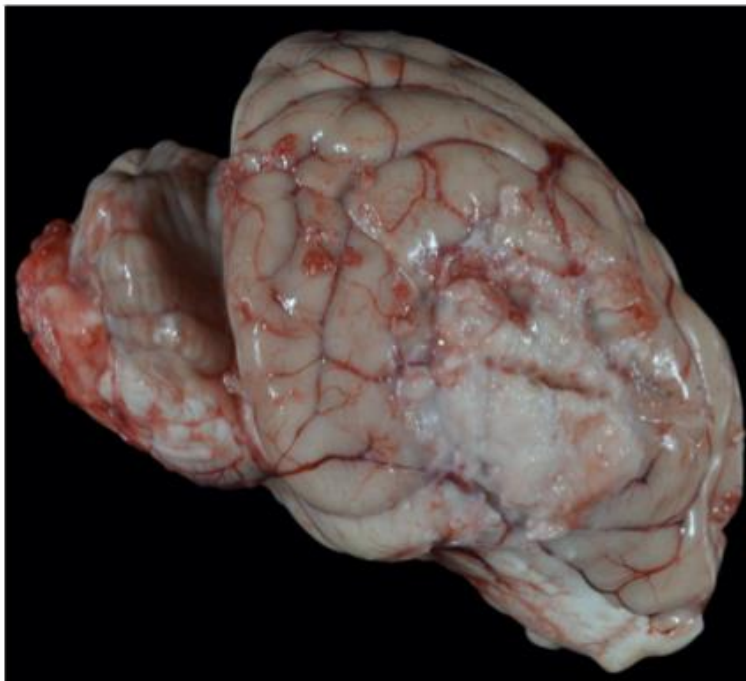
Question Sheet

Case #: **166** Month: **June** Year: **2021**

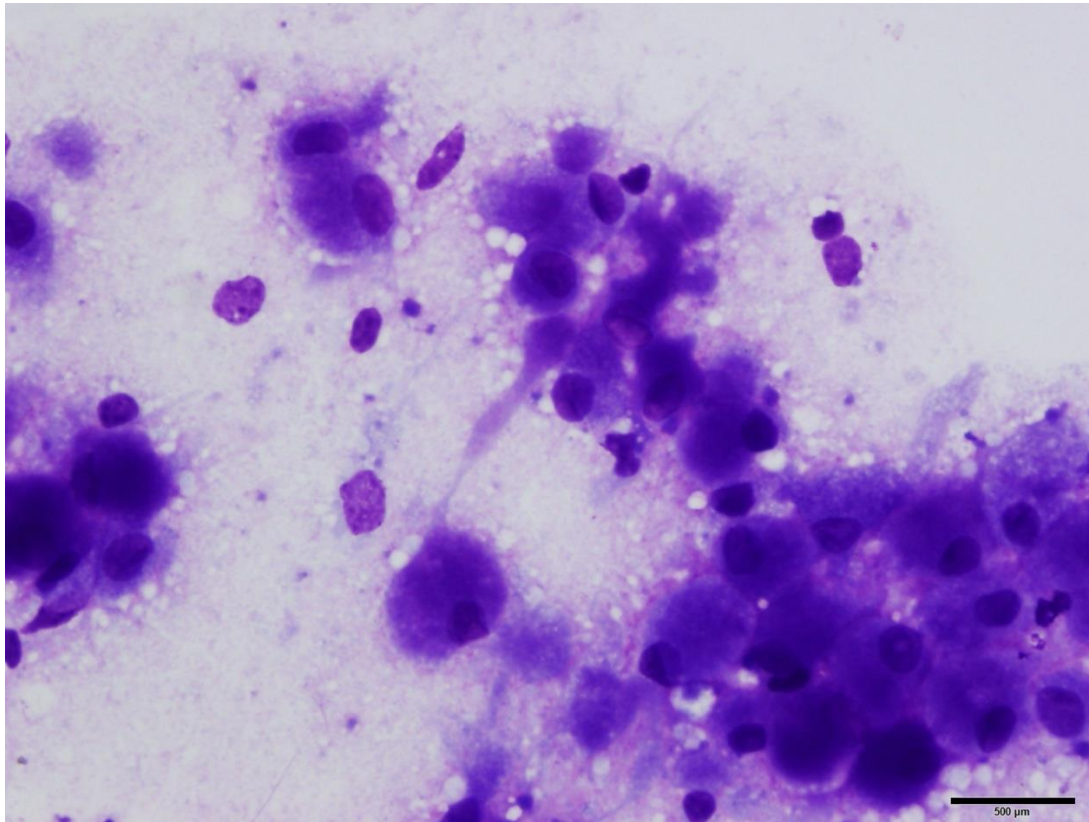
Contributors: Marisa Maglaty DVM, Kevin D. Woolard DVM, PhD, DIP ACVP
[Email: mamaglaty@ucdavis.edu]

Clinical History: 10 year-old, female spayed, Golden Retriever/Poodle mix
This patient had a mass removed laparoscopically from the right adrenal gland (cortical adenoma) and was started on a low dose of prednisone post-operatively. Eight days post-op, she began having cluster seizures and was started on levetiracetam therapy. The following day, the dog was moderately obtunded and stumbling. On neurological examination, mild generalized ataxia was noted along with decreased menace OS, and delayed proprioception in the left pelvic and left thoracic limbs. CBC and chemistry values were unremarkable except for a mild hepatic enzyme elevation. EEG showed seizure-like activity and abnormal brain waves resembling sleep state while awake. MRI revealed an eccentric right-sided mass extending over the frontal and parietal lobes with subtentorial herniation. Due to poor prognosis, euthanasia was elected.

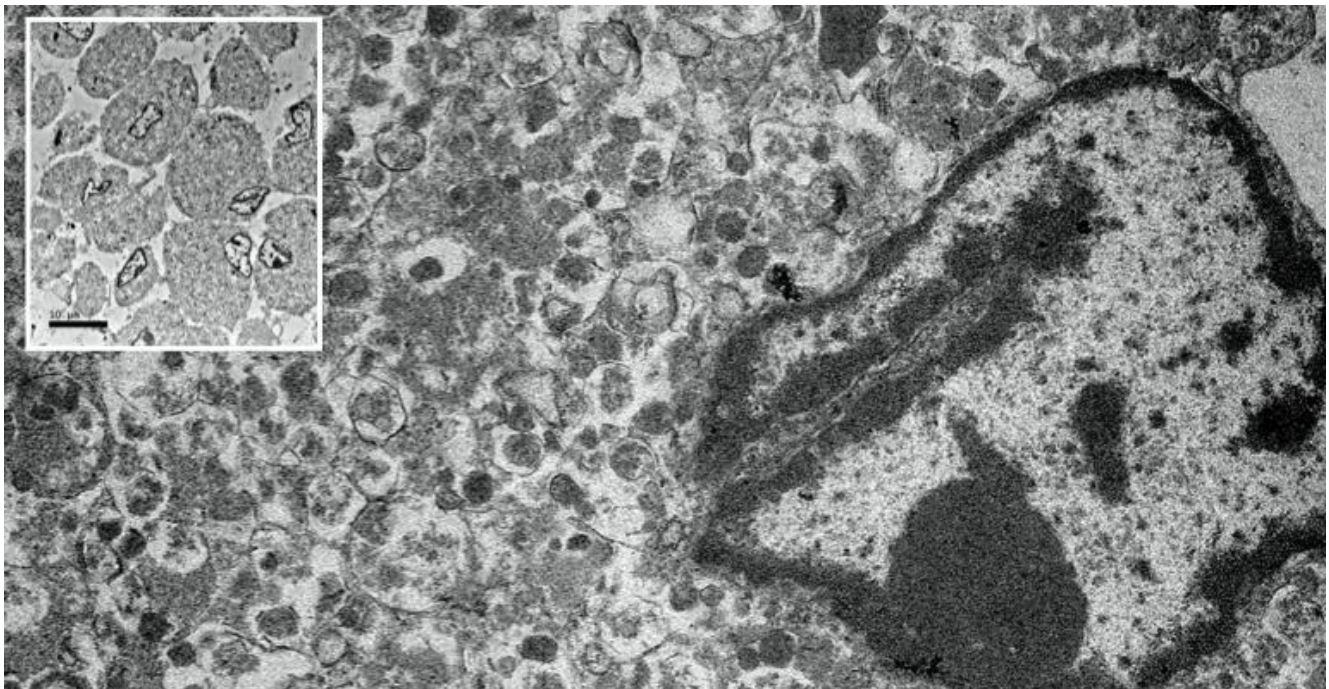
Necropsy Findings: Tenuously adhered to the right parietal lobe of the brain and the dura mater is a soft, round, white, plaque-like mass measuring 3.5 x 3.0 x 0.3 cm. The mass is friable and poorly-demarcated from surrounding brain parenchyma. A portion of the mass adheres to the supradjacent surface of the calvarium.



Impression smear:



Ultrastructure:



Follow-up questions:

1. Provide differential diagnoses for the gross and imaging results alone
2. Give a cytologic description of the impression smear/cytology
3. Describe the ultrastructural characteristics
4. Refine, and state your top differential given the cytological and ultrastructural character

*The Diagnostic Exercises are an initiative of the Latin Comparative Pathology Group (LCPG), the Latin American subdivision of The Davis-Thompson Foundation. These exercises are contributed by members and non-members from any country of residence. - Consider submitting an exercise! - A final document containing this material with answers and a brief discussion will be posted on the CL Davis website (http://www.cldavis.org/diagnostic_exercises.html).

Editor-in-chief: Claudio Barros

Associate Editor for this Diagnostic Exercise: Patricia A. Pesavento