

Diagnostic Exercise

From The Davis-Thompson Foundation*

Case # **191**; Month: **June**; Year: 2022

Contributors: Harlan Hallamys C de Lima Nascimento*, DVM, MS, Doctor in Veterinary Pathology, Mariana Martins Flores*, DVM, MS, Doctor in Veterinary Pathology. *Laboratory of Veterinary Pathology, Universidade Federal de Santa Maria (UFSM), Santa Maria, Rio Grande do Sul, Brazil. mariana.flores@ufsm.br

Clinical History: This 3-year-old female poodle was one month pregnant. It had a single episode of vomiting. The next day, the owner noticed the dog was apathic and fell down, not being able to get up. It died on the way to the hospital. No information regarding vaccination history and deworming were provided.

Necropsy Findings: A small amount of translucent blood-stained fluid was within the abdominal cavity. Several deep and superficial lymph nodes were edematous and hemorrhagic on cut surface. Multiple red fibrin strands were adhered to the intestinal serosa and liver capsule (Figure 1). The intestines had a discretely granular serous surface, and the mucosa was hemorrhagic (Figure 2). The liver was slightly enlarged and congested, had a slightly granular capsular surface and was friable on cut surface (Figure 3). Other organs were unremarkable.

Gross and/or microscopic image(s):

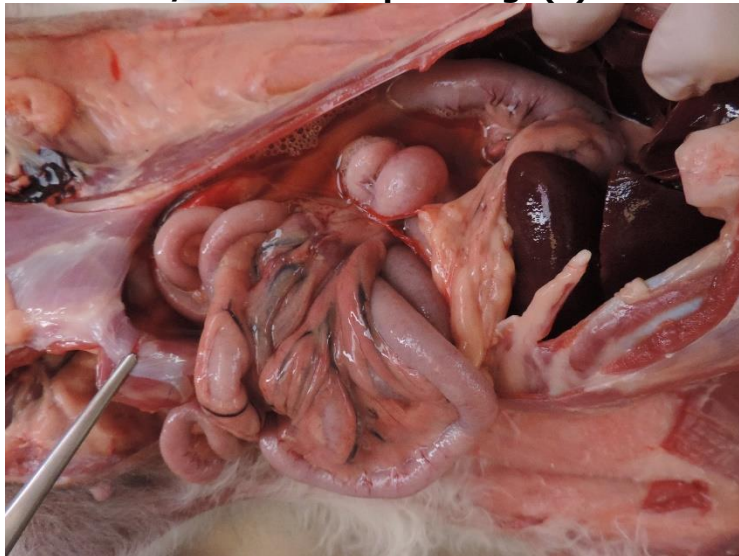


Figure 1

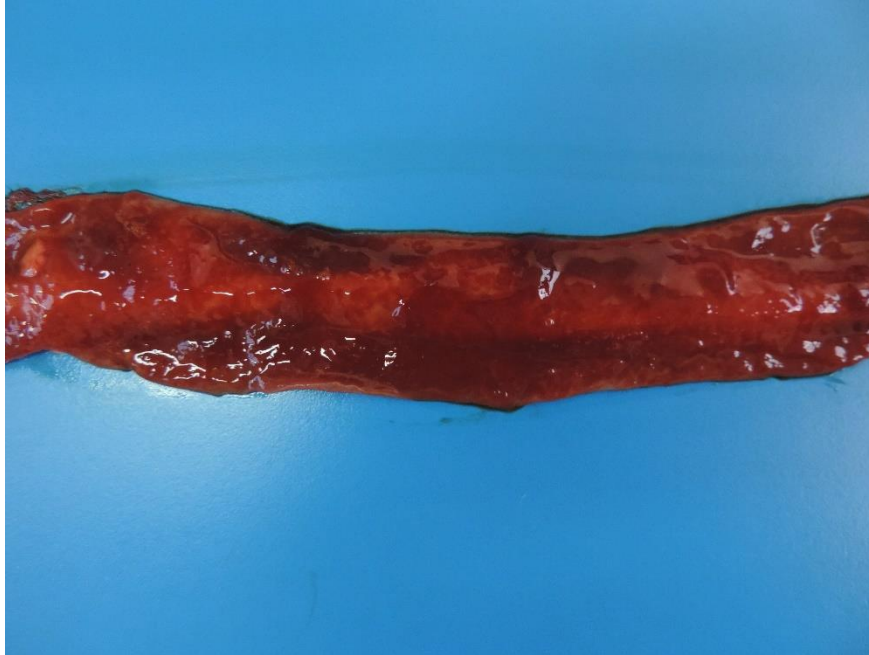

Figure 2

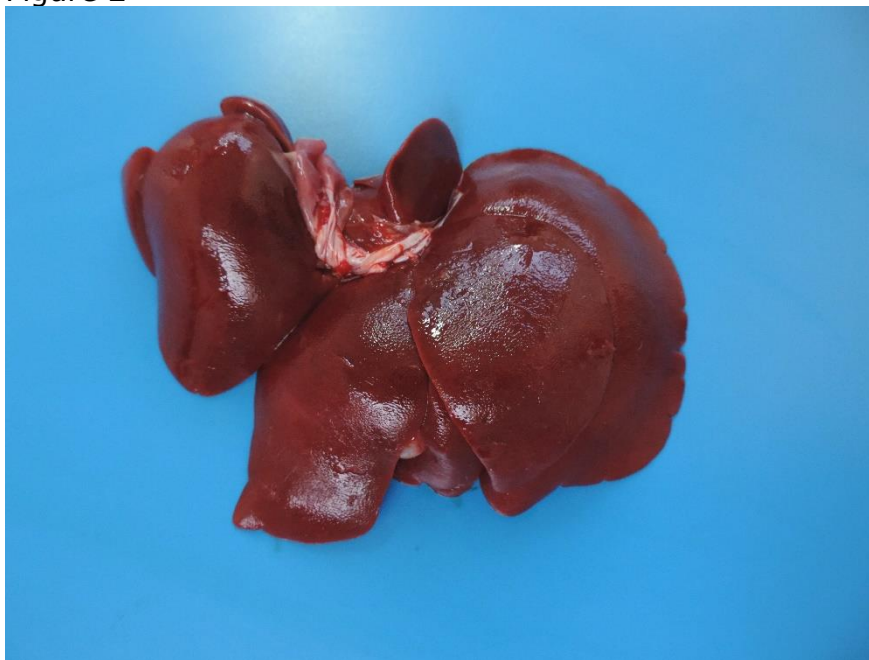

Figure 3

Follow-up questions:

1. Name hepatic diseases that could be included as possible diagnoses in this case.
2. What histologic change would you expect in the liver in these conditions?
3. What histologic hepatic changes would help differentiate these conditions?
4. What abnormalities would you expect in serum biochemistry tests?

The Diagnostic Exercises are an initiative of the Latin Comparative Pathology Group (LCPG), the Latin American subdivision of The Davis-Thompson Foundation. These exercises are contributed by members and non-members from any country of residence. Consider submitting an exercise! A final document containing this material with answers and a brief discussion will be posted on the CL Davis website (<https://davisthompsonfoundation.org/diagnostic-exercise/>)

Associate Editor for this Diagnostic Exercise: Mariana Flores

Editor-in-chief: Claudio Barros



