

Managing Editors:
S. Shrader, DVM, PhD
J. Leal, DVM, MSc, PhD
J. Asin, DVM, PhD

davisthompsonfoundation.org

Senior Editor:
F.A. Uzal, DVM, MSc, PhD



**Davis-Thompson
Foundation**

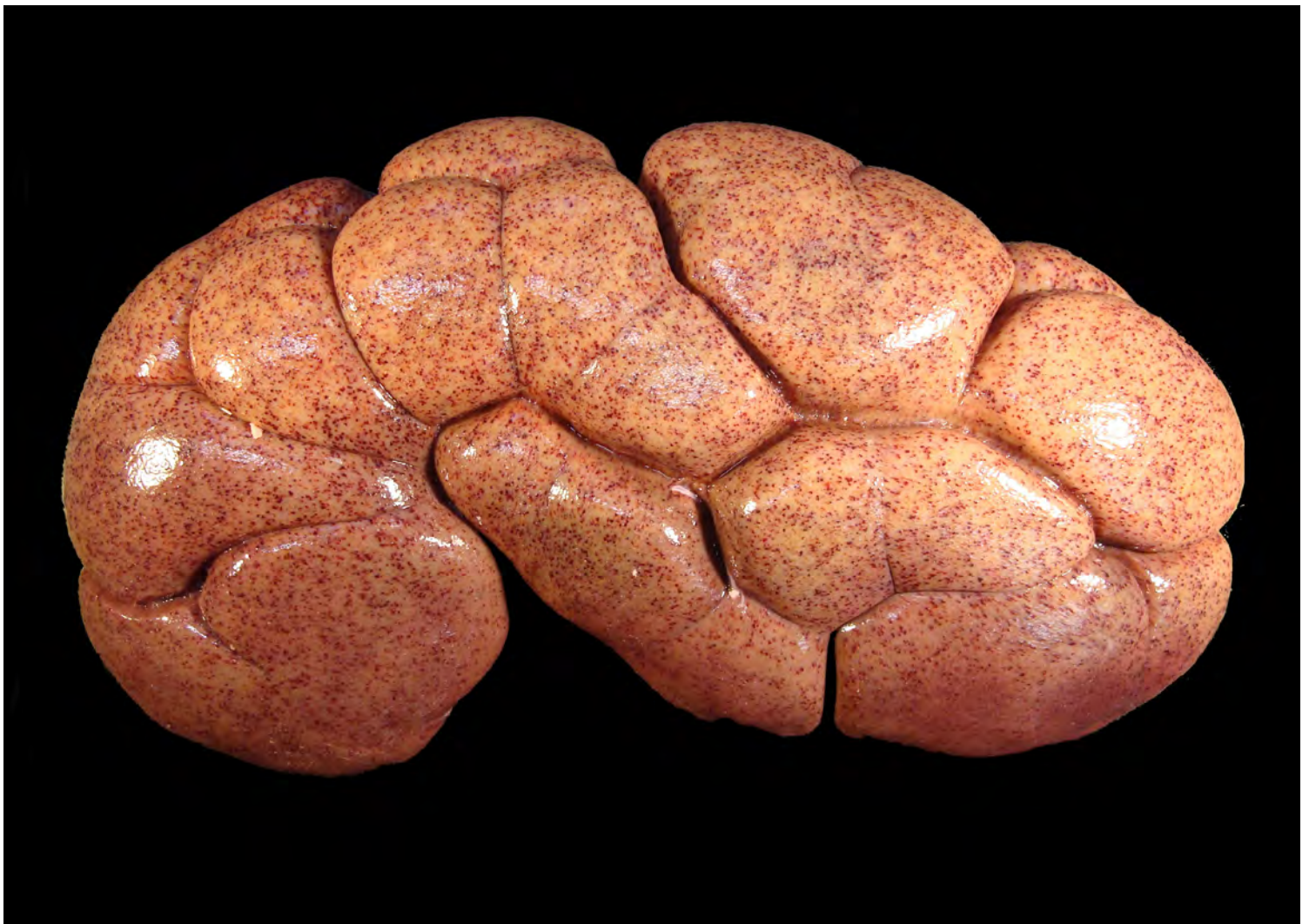C.L. DAVIS/S.W. THOMPSON
DVM FOUNDATION

A tax-exempt, donative,
publicly-supported charity
For the advancement of veterinary
and comparative pathology

THE DAVIS-THOMPSON FOUNDATION NEWSLETTER

February 2022

VOL. 52



INSIDE THIS ISSUE

Monthly cover photograph winner: Bert De Jonge

Institution: Department of Pathobiology, Pharmacology and Zoological Medicine,
Faculty of Veterinary Medicine, Ghent University

Signalment: 2-year-old Blonde D'Aquitaine cow with hemorrhagic diarrhea,
hemolytic anemia, and icterus

Diagnosis: Acute tubular necrosis due to acorn intoxication

- 3 Seminar Reviews
- 6 Diagnostic Exercise
- 8 Australian Seminar Series
- 9 Costa Rican Meeting
- 10 Spanish Seminar Series
- 11 Eastern European Vet Path Meeting
- 12 BSTP Corner
- 15 IDEXX CaseConnexx Corner
- 16 Veterinary Pathology: Call For Manuscripts
- 17 Miscellaneous Announcements

CEO & CHAIRMAN OF THE BOARD
FRANCISCO A. UZAL, DVM, MSc, PhD

PRESIDENT
JEY KOEHLER, DVM, PhD

TREASURER
BRUCE H. WILLIAMS, DVM

BOARD MEMBERS

AUTRAN, RACHEL

BRAYTON, CORY

BRICE, ANGELA

BRITT, JAMES

BROWN, CORRIE C.

CARREIRA, VINICIUS

CARVALLO, FRANCISCO

CHAPMAN, JENNIFER

DARK, MICHAEL

DE NEGRI, RAFAELA

DEL PIERO, FABIO

DEMPSEY, STEPHEN M.

EDWARDS, JOHN

GENDRON-FITZPATRICK, ANNETTE

HYMAN, ROBERT

JEONG, KYU-SHIK

LANGOHR, INGEBORG

LOMBARDINI, ERIC

LYLE, TIFFANY

MCINNES, ELIZABETH

MCNAMARA, TRACEY S.

MÍRA, MÁNDOKI

OJOK, LONZY

PESAVENTO, PATTY

PRIESTNALL, SIMON

RAC, VLADISLAVA S.

ROSS, TONY

SCOTT, DANA

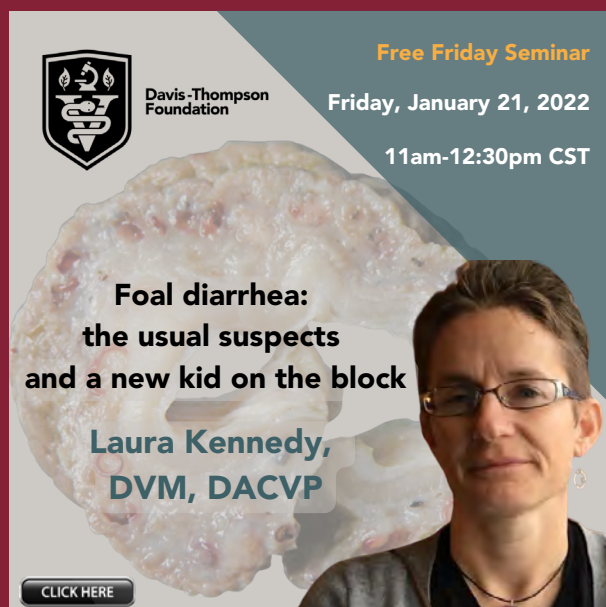SIMKO, ELEMIR

SLAOUI, MOHAMED

STROMBERG, PAUL

ZADOK, RUBEN

SEMINAR REVIEWS



Foal diarrhea: the usual suspects and a new kid on the block

Review by Dr Laura Setyo

On 21st January 2022, I was lucky enough to moderate an engaging and spirited webinar on the major causes of diarrhea in foals, presented by Dr Laura Kennedy (University of Kentucky, United States). Her webinar covered the major players and then threw in a “new kid on the block.”

Opening with an introduction on the merits of diagnostic pathology (and why every diagnostic pathologist should consider themselves an Agatha Christie of some variety), she took us on a journey from Salmonellosis to sepsis. No one ever wants to think about diarrhea in detail – unless you’re on a pathologist! Dr Kennedy’s descriptions of watery diarrhea in the rotavirus-inflicted foal and fetid Clostridial diarrhea in a horse’s furry cousin were succinct and memorable.

The pièce de résistance was the discussion around a Kentucky disease outbreak. I love discovery stories and the narrative of a nascent novel pathogen is always an exciting one. It appeals to the sense of scientific curiosity in every pathologist, and the story behind this pathogen did not disappoint! What pathogen was it? I’ll keep you guessing for now - you’d better watch the playback on our YouTube channel to find out.

Overall, a fun Friday webinar with great interactive segments and high audience engagement. We’re grateful to Dr. Kennedy for taking the time to present on this important topic to us and we’ll see you at the next Friday webinar!

SEMINAR REVIEWS



Equine dental histology



DR. CHARLES SCHWARTEN

From ontogenesis to some of the most common disease entities

On January 7th, Major Schwarten gave an outstanding and thorough lecture, where he reviewed the gross and microscopic anatomy of the equine teeth, described some usual normal findings and explained disease entities such as EOTRH, nodular hypercementosis and apical tooth root abscesses.

Do not lose the opportunity to watch this webinar! It will be rebroadcasted on our Youtube Channel during the next six months.

.....

"A unique presentation which shows a tremendous amount of effort over a long period of time. Bravo!"

"The seminar was excellent. Tough topic, very well presented"

"Wonderful presentation. I look forward to the presentation at this year's ACVP meeting and to future publications on this topic!"

SEMINAR REVIEWS

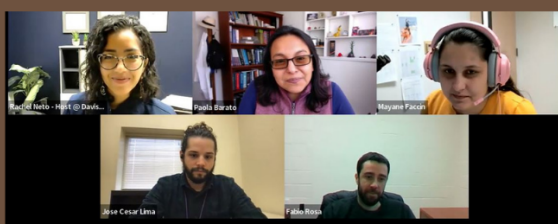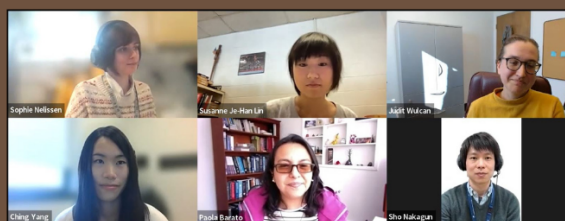VIRTUAL ROUNDTABLE:

APPLYING FOR US VETERINARY PATHOLOGY RESIDENCY PROGRAMS AS AN INTERNATIONAL CANDIDATE. EXPERIENCES AND RECOMMENDATIONS / Q&A SESSION

27-28 January 2022

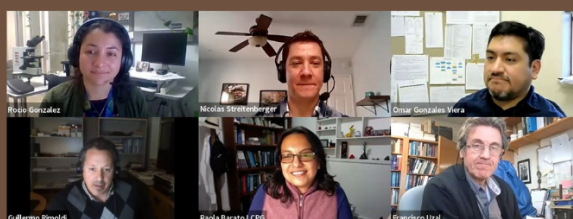By Rachel L. Autran L. T. Neto

This phenomenal initiative brought to our community by the Latin Comparative Pathology Group (LCPG) and the D-T Foundation was a big hit for many people worldwide who aspire to apply for a residency program in the U.S.! The panelists answered dozens of questions about the entire process, including documentation, brilliant tips, highs and lows, and daily residency life. We all wish we had this same discussion when we applied to our programs, so we hope participants enjoyed this virtual gathering!



¡Esta fenomenal iniciativa compartida con nuestra comunidad por el Grupo Latino de Patología Comparada (LCPG) y la Fundación D-T ha sido un gran éxito para muchas personas en todo el mundo que desean aplicar a un programa de residencia en los EE. UU.! Los panelistas respondieron docenas de preguntas sobre todo el proceso, incluida la documentación, los buenos consejos, los altibajos y la vida cotidiana de la residencia. Todos deseamos haber tenido esta misma discusión cuando nos inscribimos en nuestros programas, ¡así que esperamos que los asistentes hayan disfrutado de esta reunión virtual!

Esta iniciativa fenomenal compartilhada com nossa comunidade pelo Latin Comparative Pathology Group (LCPG) e pela D-T Foundation foi um grande sucesso para muitas pessoas ao redor mundo que desejam se inscrever para um programa de residência nos EUA! Os panelistas responderam a dezenas de perguntas sobre todo o processo, incluindo documentação, dicas brilhantes, altos e baixos e sobre a vida diária da residência. Todos nós queríamos ter tido essa mesma discussão quando nos inscrevemos em nossos programas, por isso esperamos que os participantes tenham gostado deste encontro virtual!





DIAGNOSTIC EXERCISE



Case #: **178** Month: **December** Year: **2021**
Question Sheet

Contributors: Ticiana Brasil Ervedosa¹, BVSc; Pedro Enrique Navas-Suárez^{1,2}, BVSc, MSc, PhD candidate; Eduardo Ferreira Machado^{1,2}, BVSc, PhD candidate; Ticiana Zwarg³, BVSc, MSc; Isis Paixão de Jesus¹, BMSc, MSc; Julia de Carvalho¹, BSB; Juliana Mariotti Guerra¹ BVSc, MSc, PhD; Natália C.C. de A. Fernandes^{1,2}, BVSc, MSc, PhD candidate (nccafernandes@yahoo.com.br) ¹Pathology Division, Adolfo Lutz Institute, São Paulo, Brazil. ²Laboratory of Wildlife Comparative Pathology (LAPCOM), Department of Pathology, School of Veterinary Medicine and Animal Science, University of São Paulo. ³Wildlife Division - São Paulo City Hall, São Paulo, Brazil.

Clinical history: a free-ranging South American coati (*Nasua nasua*) was found on a farm, apparently injured. Clinical examination at the Wildlife Division revealed cachexia, alopecia along the dorsal neck, suggestive of scabies, secretion in the oral cavity, and neurological signs (locked jaw, paraplegia, unresponsiveness to physical restraint). Due to poor prognosis, euthanasia was performed. After necropsy, tissue samples were sent to the Pathology Division of the Adolfo Lutz Institute in São Paulo, Brazil, as part of a wildlife disease surveillance program.

Gross image:

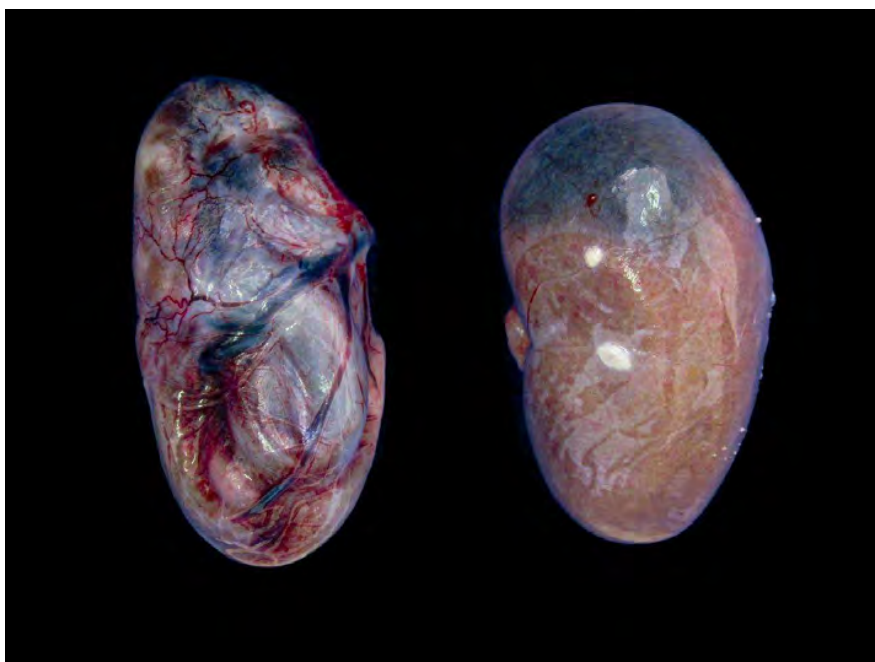

Figure 1. Right kidney on the left and left kidney on the right.



DIAGNOSTIC EXERCISE



Microscopic images:

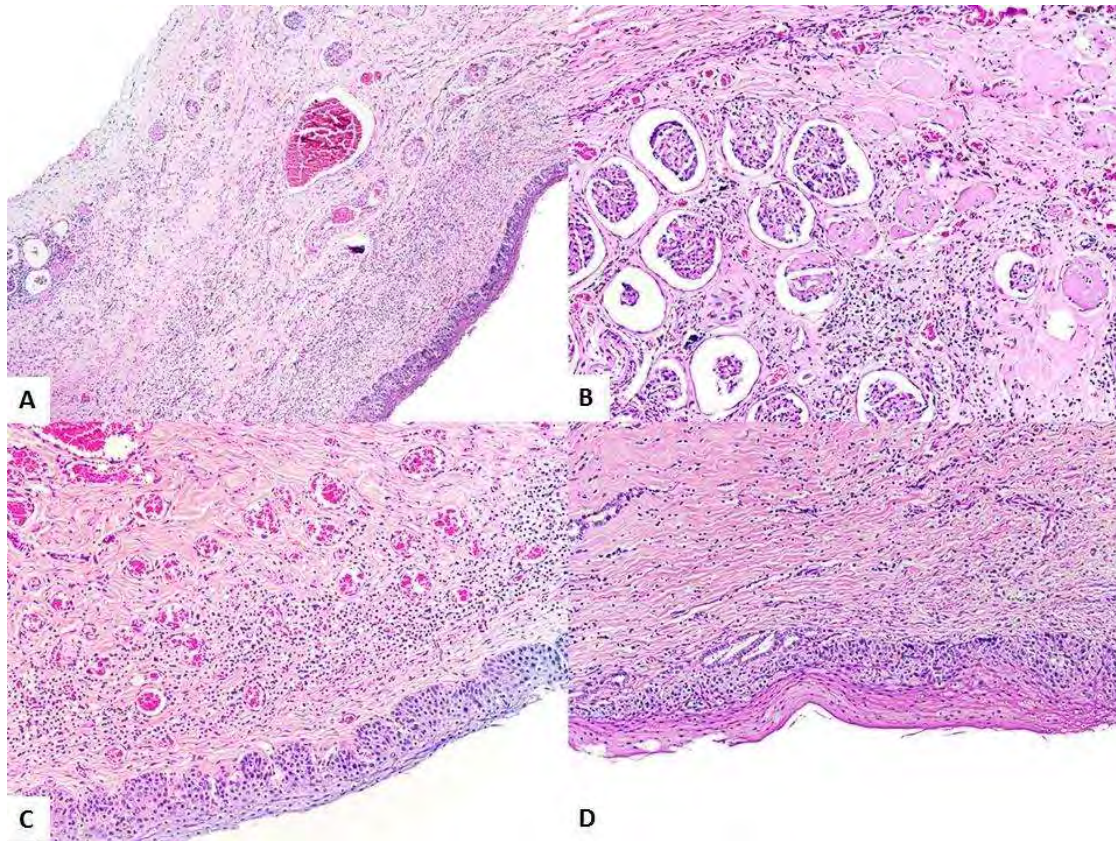


Figure 2. A, B, C and D: Kidney sections, H&E stain.

Follow-up questions:

- (1) *Microscopic description*
- (2) *Morphologic diagnosis*
- (3) *Etiology*

[Click here for answers](#)

AUSTRALIAN SEMINAR SERIES

Australian Seminar Series

USA: Friday, February 25, 7-9pm CST

Australia: Saturday, February 26 12-2pm AEDT/
9-11am AWST

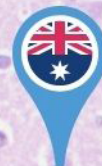

Davis-Thompson
Foundation

Bugs, pugs, and drugs: an overview of inflammatory neurologic disorders



Jey Koehler
DVM, PhD, DACVP



[Click here to
register](#)


COSTA RICAN MEETING

1st Costa Rican Meeting of the Davis-Thompson Foundation

Híbrido: 25 - 26 Febrero, 2022

Escuela de Medicina y Cirugía Veterinaria San

Francisco de Asís: 27 Febrero, 2022



¡Charlas en español!



Francisco Uzal
DVM, MSc, PhD, DACVP

Leonardo Minatel
DVM, PhD



Días 25 y 26: Gratuito por Zoom o \$20 USD en persona

Día 27: \$10 USD Práctica en persona

Aprobado para 13 créditos del Colegio de Médicos Veterinarios de Costa Rica

Patrocinadores:

CAPRIS MEDICA
Interando en Diagnóstico e Investigación

Diagnóstico Albeitar
Laboratorio Clínico y Referencia

verlab
PRO PLAN

Diprolab
Laboratorio Clínico

Hill's
Transformando vidas



VETIM
Salud y Bienestar Animal

Click here to
register

SPANISH SEMINAR SERIES



Davis-Thompson
Foundation



Spanish Seminar Series

seminarios en español
10:00am-11:30am CDT



MZO ::::

24

**Serie especial teórico práctica:
Dermatopatología básica 1: inflamacion**
Joaquin Ortega, DVM, PhD, DACVP



ABR ::::

28

**Serie especial teórico práctica:
Dermatopatología básica 2: neoplasias**
Joaquin Ortega, DVM, PhD, DACVP



MAY ::::

19

Revisión de patología endócrina
Phillip Sponenberg, DVM, PhD



JUN ::::

23

Plantas tóxicas en Sudamérica
Franklin Riet-Correa, DVM, PhD
Ernesto Odriozola, DVM, MS Phil

Click here to
register for individual
seminars

EASTERN EUROPEAN VET PATH MEETING

**Faculty of Veterinary Medicine, Ss. Cyril
and Methodius University in Skopje and
Davis-Thompson Foundation**

3rd Annual Davis-Thompson Foundation Eastern European Veterinary Pathology Meeting

25-27 MAY 2022

Hotel Sileks, Ohrid, R. North Macedonia



**Registration fee 100 EUR
Discounted hotel rates when booked
before 31st March 2022**

Information and Registration

<https://fvm.ukim.edu.mk/en/3rd-dtf-2022/>



**Francisco
Uzal**
**DVM, MSc, PhD,
DACVP**

Bovine pathology
Alimentary diseases
of domestic animals



**Monika
Welle**
**DVM, DECVP,
Prof. Dr. med. vet.**

Dermatopathology



**Trpe
Ristoski**
DVM, PhD

Infectious diseases
of dogs and cats

**Click here to
register**

BSTP CORNER



Virtual CES 5: Female Reproductive System Tuesday 8th – Thursday 17th March 2022

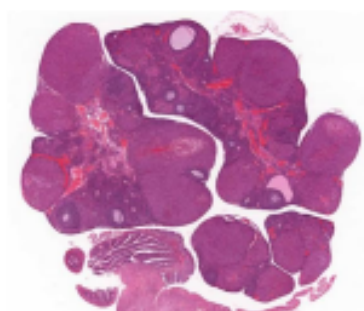
CES 5 will be held over two weeks using Zoom – on the afternoons of Tuesday 8th, Wednesday 9th, Thursday 10th, Tuesday 15th, Wednesday 16th and Thursday 17th March 2022, from 13.00 – 16.30/17.00 (GMT+0, London/UCT+0) each day.

Continuing Professional Development: Approved by the Royal Society of Biology for purposes of CPD, this event may be counted as 53 CPD Credits.

Approximately 17.5 hours of educational activity will be recorded on Attendance Certificates. For those delegates who wish to self-accredit for CPD, proof of attendance should be retained for this purpose.

This Continuing Education Symposium will give you the opportunity to learn about species differences in the female reproductive tract as well as sexual immaturity, reproductive senescence, neoplasia and related International Harmonization of Nomenclature and Diagnostic Criteria (INHAND) nomenclature. We will also cover regulatory Developmental and Reproductive Toxicology (DART) study packages and endocrine disruption. You will have direct access to international key speakers and exposure to pharmaceutical, agrochemical and biotechnology case studies.

Access to the downloadable course materials and Zoom login information will be provided to all those registered up to one week in advance of the symposium.



Registration is still open; early bird registration ends at midnight on 4th February 2022 – with registration closing at midnight on 18th February 2022.

If you would like further information, have any queries or would like to reserve a place, please contact the BSTP Secretariat – bstpsecretariat@gmail.com

or visit <http://www.bstp.org.uk/events/ces-5-female-reproductive-system/>

BSTP CORNER



Virtual CES 6: Male Reproductive System Tuesday 5th – Thursday 14th July 2022

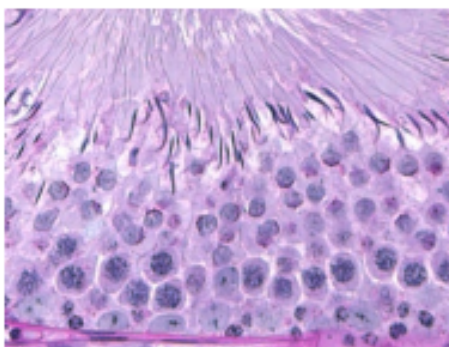
CES 6 will be held over two weeks using Zoom – on the afternoons of Tuesday 5th, Wednesday 6th, Thursday 7th, Tuesday 12th, Wednesday 13th and Thursday 14th July 2022, from 13.00 – 16.30 (GMT+1, London/UCT+1) each day.

Continuing Professional Development: Approved by the Royal Society of Biology for purposes of CPD, this event may be counted as 53 CPD Credits.

Approximately 17.5 hours of educational activity will be recorded on Attendance Certificates. For those delegates who wish to self-accredit for CPD, proof of attendance should be retained for this purpose.

This Continuing Education Symposium will cover an overview of the male reproductive system in preclinical animal species.

Access to the downloadable course materials and Zoom login information will be provided to all those registered up to one week in advance of the symposium.



Detailed information, including the programme and a registration form will be available soon.

If you would like further information, have any queries or would like to reserve a place, please contact the BSTP Secretariat – bstpsecretariat@gmail.com

or visit <http://www.bstp.org.uk/events/ces-6-male-reproductive-system/>

BSTP CORNER



Here are 5 reasons why you should attend virtual events organised by the BSTP:

Easy access and inclusivity – with current travel restrictions, delegates who live in remote parts of the world and would not otherwise be able to travel to the UK can now attend.

Sustainability – attending the event from home or your office means fewer planes, trains and cars which helps reduce everyone's carbon footprint.

Cost effective – no travel and accommodation for you to book adding to the cost of the event.

Reduced logistical effort – saving time both for you being away from your family and anyone who organises your travel and accommodation.

Networking – still have contact with the speakers and benefit from their experience.

So, break out of your comfort zone to learn something new and invest in yourself to improve your employment opportunities!

Future BSTP events are due to take place in:

8th – 17th March 2022	CES 5 - Female Reproductive System
5th – 14th July 2022	CES 6 - Male Reproductive System
10th & 11th November 2022	37th Annual Scientific Meeting & AGM – Digital Pathology and Mouse Pathology Workshop
March 2023	CES 7 - Infectious diseases in laboratory animals
July 2023	CES 8 - Nervous System
November 2023	38th Annual Scientific Meeting & AGM
March 2024	CES 9 - Urinary System
July 2024	CES 10 - Digestive System
November 2024	39th Annual Scientific Meeting & AGM
March 2025	CES 11 - Cardiovascular System
July 2025	CES 12 - Endocrine System
November 2025	40th Annual Scientific Meeting & AGM
March 2026	CES 13 - Urinary System
July 2026	CES 14 - Lymphoid & Haematopoietic Systems
November 2026	41st Annual Scientific Meeting & AGM
March 2027	CES 15 - Musculoskeletal System & Skin

The order of the CES will depend on the availability of high-quality speakers who are world experts in their particular field to present at the relevant meeting.

If you would like to receive information on any of these events as soon as the information becomes available, you need to make sure that the BSTP have your contact details on the mailing list.

You can withdraw your consent to receive communications from the BSTP at any time, by means

IDEXX CASECONNEX CORNER

Signalment: 9-year-old, female, snake not otherwise specified

Source/ History: Patient has regurgitated multiple times recently. Patient is one of a group of about 20 snakes. No other snakes are symptomatic at this time

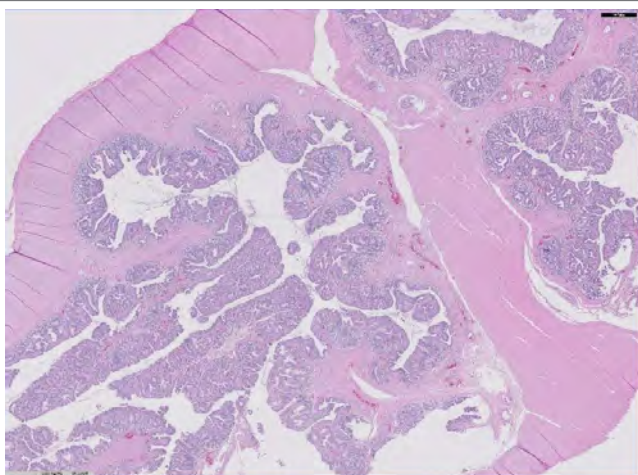


Figure 1. (2X magnification, H&E stain) The gastric mucosa is thickened with prominent rugal folds.

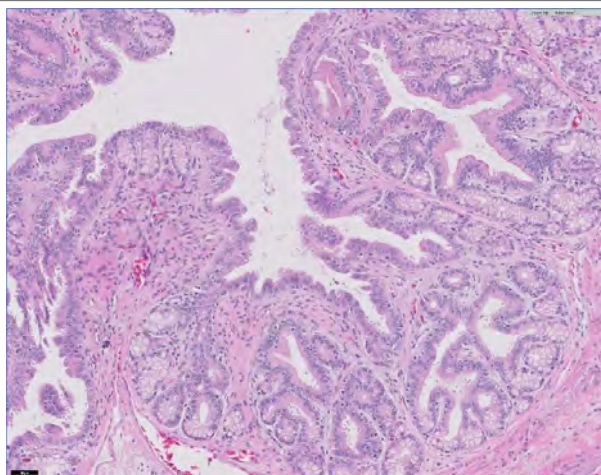
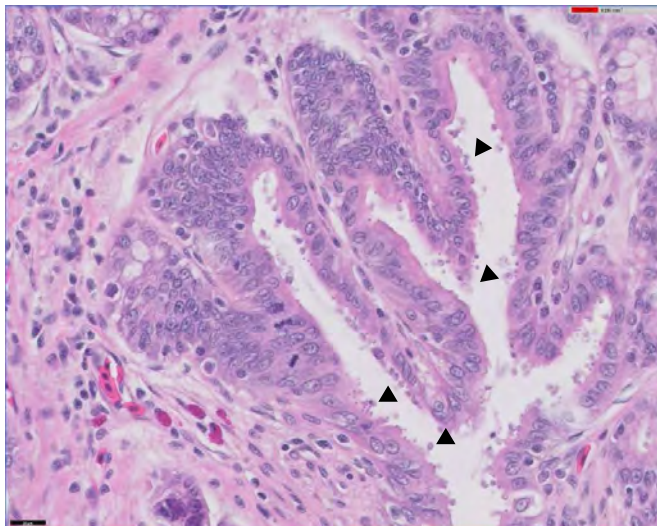


Figure 2. (20X magnification, H&E stain) Gastric pits are variably elongated with mild dilation and occasional branching.



Microscopic Description:

The gastric mucosa is moderately to markedly hyperplastic and thickened with prominent rugal folds. Gastric pits are multifocally elongated and occasionally mildly dilated with branching. There is multifocal piling of luminal epithelial and mucus neck cells. Multifocally along the surface there are moderate to marked numbers of protozoa. These protozoa are round, 3 to 6 µm in diameter, with a central round basophilic nucleus. These structures are adhered to the luminal epithelium as well as the epithelium of the gastric glands and pits. Within the lamina propria and multifocally in the submucosa are mild to moderate numbers of granulocytes and fewer lymphocytes and plasma cells. There is multifocal edema in the submucosa.

Microscopic Interpretation:

Moderate to marked, chronic hypertrophic gastritis with mild to moderate granulocytic and lymphoplasmacytic gastritis and myriad intralesional protozoa consistent with *Cryptosporidium* spp.

Figure 3. (60X magnification, H&E stain) Adhered to the epithelium of the gastric pits and glands are many 3 to 6 µm in diameter round protozoa (black arrowheads). There is mild piling of the epithelium lining gastric pits and glands.

Comments:

Histologic examination of stomach sample revealed a hypertrophic gastritis with intralesional organisms consistent with *Cryptosporidiosis*.

Cryptosporidium spp. is an apicomplexan parasite that is known to affect many different species. Two main *Cryptosporidium* spp. are frequently reported in reptiles: *Cryptosporidium serpentis* and *Cryptosporidium varanii* (*saurophilum*). *Cryptosporidial* infections are an important cause of gastric, and occasionally enteric, disease in snakes. Common clinical signs include weight loss and regurgitation. On gross examination, the gastric mucosa is thickened with prominent rugal folds and luminal mucous accumulation.

Reference: Brownstein DG et al. *Cryptosporidium* in snakes with hypertrophic gastritis. Vet Pathol. 1977 Nov;14(6):606-17; Terio, K. A., McAloose, D., & St. Leger, J. (Eds.). (2017). Pathology of wildlife and zoo animals. Academic Press.

VETERINARY PATHOLOGY: CALL FOR MANUSCRIPTS ON VETERINARY AND COMPARATIVE DERMATOPATHOLOGY

Veterinary dermatopathology is a growing discipline that has become well established in the past thirty years. The pathologist-dermatologist relationship is crucial for dermatopathology work. The broad scope of cutaneous disorders ranging from inflammatory, dysplastic, degenerative to neoplastic is the great challenge in dermatopathology, but also what make every day unique and captivating. Over the past years, several foundational veterinary dermatopathologists have retired leaving a need to train a new generation in this fascinating field. The main goal of this special issue is to build a community of authors and readers to develop a network that will contribute to continued advancements, new ideas and research directions.

The journal, *Veterinary Pathology*, is issuing a call for manuscripts for a special focus on the topic of "Veterinary and Comparative Dermatopathology" and encourages submission of relevant review papers or primary research.

Veterinary Pathology is the journal of the American College of Veterinary Pathologists, the European College of Veterinary Pathologists, and the Japanese College of Veterinary Pathologists.

Reviews and research manuscripts for the special issue should focus on one or more of:

- insights on pattern analysis in veterinary dermatopathology;
- naturally occurring inflammatory or neoplastic skin diseases of animals, or laboratory animal models that contribute to the understanding of these conditions;
- light, fluorescence, and electron microscopy, immunohistochemistry, immunology, molecular biology, and genetics, provided the principal focus is dermatopathology;
- address disease mechanisms (pathogenesis, pathophysiology), pathologic findings and/or correlations among pathologic, clinical and laboratory findings;
- highlight diagnostic approaches to challenges in veterinary and comparative dermatopathology (e.g. alopecia, vasculitis, interface dermatitis)
- comprehensive reviews of a topic relevant to diagnostic dermatopathology in domestic animals.

Authors are invited to send a statement of interest including a title and short abstract (≤ 250 words) to the guest editors, Dr. Verena Affolter, Dr. Joanne Mansell, Dr. Charles Bradley, and Dr. Barbara McMahon. Statements should be sent by April 1st 2022. The guest editors will contact the corresponding author via e-mail regarding submission status and next steps.

Veterinary Pathology is the premier international publication of basic and applied research involving domestic, laboratory, wild-life, marine and zoo animals, and poultry. Bridging the divide between natural and experimental diseases, the journal details the diagnostic investigations of natural and emerging diseases of animals; reports experimental studies enhancing understanding of the mechanisms of specific processes including cancer, infection, immunologic, metabolic and genetically mediated diseases; provides unique insights into animal models of human disease; and presents studies in identification and characterization of environmental (food, plant and chemical) and pharmaceutical hazards.

Manuscripts considered for publication must:

1. have significant importance to animal and/or human health,
2. include new knowledge supported by valid data,
3. address disease mechanisms (pathogenesis, pathophysiology), or pathologic findings in important new or emerging diseases, or clinico-pathologic correlations,
4. AND be of sufficiently broad interest to be of substantial value to veterinary pathologists.

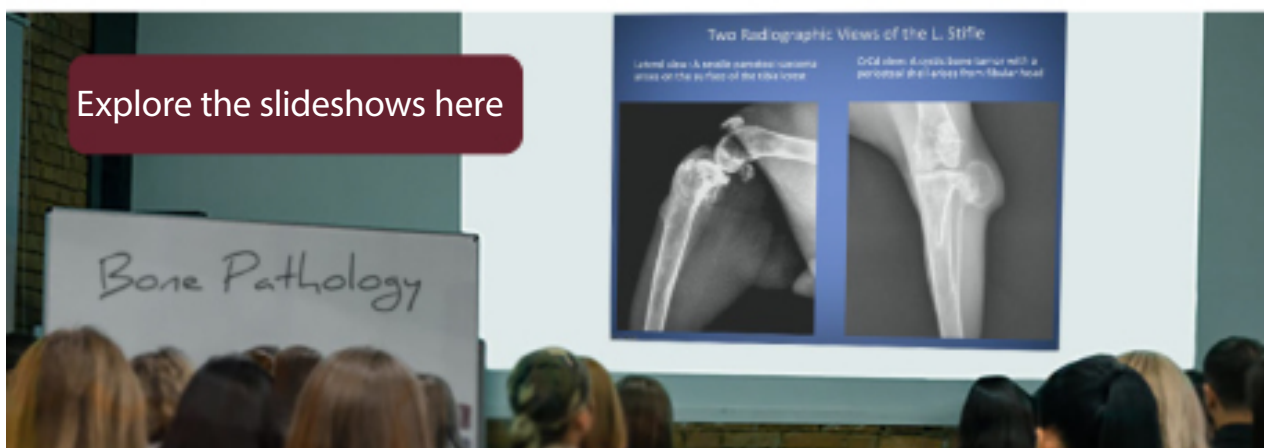
Paola Roccabianca
Editor, Veterinary Pathology

Jeff Caswell
Editor-in-Chief, Veterinary Pathology

MISCELLANEOUS ANNOUNCEMENTS

Discover an Extraordinary Compilation of Complimentary Bone Pathology Slideshows

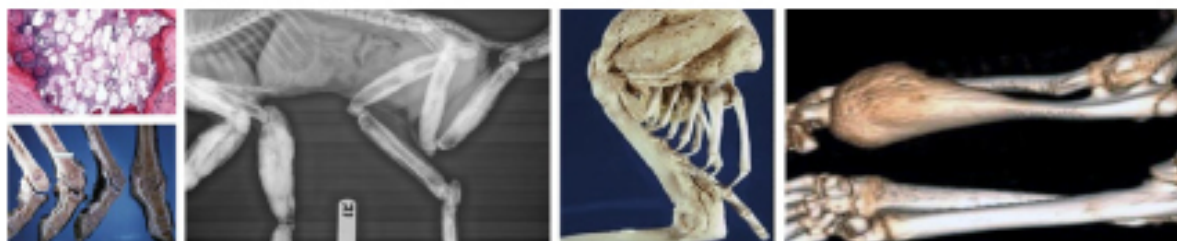Roy Pool, DVM, PhD, Clinical Professor, Veterinary Pathobiology, and the Department of Small Animal Clinical Sciences in the College of Veterinary Medicine and Biomedical Sciences at Texas A&M University, want to share an extensive group of Bone Pathology PowerPoint slideshows.



Explore the slideshows here

Dr. Pool has collected common and uncommon bone pathology cases and examples for decades. The slideshows include seminars, lectures, and collections containing thousands of images and explanations of bone tumors; lesions; oral, dental, and pharyngeal disorders and tumors; and orthopedic disorders.

Review the extensive collection, download resources of interest, and use these resources in your own lectures and presentations at: <https://veteducator.com/bone-path-library/>



Contact the Center for Educational Technologies (CET) Help Desk at cethelpdesk@cvm.tamu.edu with any questions or for technical assistance.

MISCELLANEOUS ANNOUNCEMENTS



Become a member of the Latin Comparative Pathology Group



LCPG:

- Provides Diagnostic Exercises
- Offers travel awards
- Coordinates externships in US labs for Latin Americans
- Organizes and lectures in Latin American seminars and courses

Membership Fees:

- \$50 – Professionals in US, Canada, and Europe
- \$30 – Professionals in Latin America
- \$25 – Students in US, Canada, and Europe
- \$15 – Students in Latine America

[CLICK HERE](#) to learn more.

Use this link to join: <https://davisthompsonfoundation.regfox.com/lcpg-membership>

LCPG is the proud Latin American Division of the Davis Thompson Foundation

MISCELLANEOUS ANNOUNCEMENTS

Society of Toxicologic Pathology: Trainee Mixer Preparation of Scientific Abstracts for Awards

Wednesday, February 16, 2022: 7:00 PM–8:30 PM EST

[Register online](#) by Friday, February 11, 2022



<https://absolutelymaybe.plos.org/2018/06/06/building-a-great-scientific-abstract-a-quick-checklist/>

- Network with STP mentors and fellow trainees
- Tips on optimizing scientific abstracts
 - Special presentation by STP Awards Committee
- Explore trainee opportunities at STP 2022 Annual Symposium



MISCELLANEOUS ANNOUNCEMENTS



www.vcgp.org is now live!

The goal of the website and the mission of VCGP is to improve care for animals with cancer through standardization of tumor evaluation and reporting. This website provides guidelines for assessing common parameters used in the light microscopic assessment of animal tumors as well as complete protocols recommended for investigators seeking to establish tumor grading systems. VCGP created this website to maintain these guidelines and protocols as centralized resources for veterinary anatomic and clinical pathologists to assist in reporting and gathering relevant information about aggressive tumors. Detailed protocols and guidelines are educational and research resources while the concise versions are user ready checklists for diagnosticians and editors/reviewers of manuscripts. These are living documents that will be updated and are continuations of manuscripts published by our veterinary pathologist colleagues.

See: International Guidelines for Veterinary Tumor Pathology: A Call to Action - <https://doi.org/10.1177/03009858211013712>




It's sweater weather! Grab a cozy Davis-Thompson Foundation sweater to get you through this winter and to show off the mighty pathologist that you are!

Get it [HERE](#)



...and T-shirts are still available!

MISCELLANEOUS ANNOUNCEMENTS




[CLICK HERE](#) to order your copy today!

RETIRING?

Have slides left over from your recent slide seminar? Just looking to free up some storage space? The Foundation is looking for additional glass slides, kodachromes and other similar materials for its Correspondence Division and Study Centers. All materials should be well identified with as much accompany history and discussion as possible, as these materials are expressly used for teaching. Moreover, as the Foundation is a publicly donative charity, all donated materials are tax-deductible. For more information, please contact Dr. Bruce Williams at bruce.h.williams.dvm@gmail.com.

Davis-Thompson Foundation Pathology Externship

Since 1980, the Davis-Thompson Foundation lab sites have hosted more than 125 veterinary students at 8 participating diagnostic laboratories. These students usually have a strong interest in pathology itself or zoo or poultry medicine that require a strong pathology background. The Foundation is always interested in having veterinary students apply for an externship and we would like to add more externship sites that do not usually have veterinary students, to help increase their interest and knowledge of pathology with some off-campus experience. For more information, contact Dr. Jim Britt, jobritt@sbcglobal.net; 501-912-1449.



Atlas De Parasitos Metazoarios En Tejidos Animales - Click Here to Get a Digital Download!



**Davis-Thompson
Foundation**

DAVIS-THOMPSON FOUNDATION

Phone: 847-367-4359

Fax: 847-247-1869

davis-thompsonfoundation.org

cldavisdvm@comcast.net

FEBRUARY 2022