



Diagnostic Exercise

From The Davis-Thompson Foundation*

Case #: **154** Month: **November** Year: **2020**

Title: *Intestinal adenocarcinoma in a goat, with metastases to mesenteric and tracheobronchial lymph nodes, uterus and ovary*

Contributors: Tsukasa Sakashita,¹ DVM Student; Mariano Carossino,² DVM, PhD, DACVM; Ingeborg M. Langohr,² DVM, MS, PhD, DACVP; Clare Scully,³ DVM, MS, DACT; Nobuko Wakamatsu-Utsuki,² DVM, PhD, DACPV, DACVPO

sakashita.gf14012@gmail.com

¹Department of Veterinary Pathology, Faculty of Agriculture, University of Miyazaki, Miyazaki, Japan. ²Louisiana Animal Diagnostic Disease Laboratory (LADDL) and Department of Pathobiological Sciences, School of Veterinary Medicine, Louisiana State University, Baton Rouge, LA, USA. ³Department of Veterinary Clinical Sciences, School of Veterinary Medicine, Louisiana State University, Baton Rouge, LA, USA.

Clinical History: 6-year-old, female Boer goat. The animal presented to the LSU Veterinary Teaching Hospital with lethargy, abdominal distension, and diarrhea. Physical exam revealed a fluid wave and chemosis. Due to the severity of her condition, humane euthanasia was elected.

Necropsy Findings: The serosa of the small intestine had multifocal, white, 2 to 4 mm, firm nodules. The mucosa of the ileum was multifocally thickened with prominent yellow to pale pink mucosal folds. The mesenteric lymph nodes were enlarged 2-3 times and firm. The peritoneal cavity contained approximately 6 L of clear, yellow fluid with occasional clear, flocculent material. Other findings included focally extensive necrotizing rumenitis and fibrinous peritonitis, lymphoplasmacytic abomasitis, bronchopneumonia, and tracheobronchial lymphadenomegaly.

Gross and Microscopic Images:

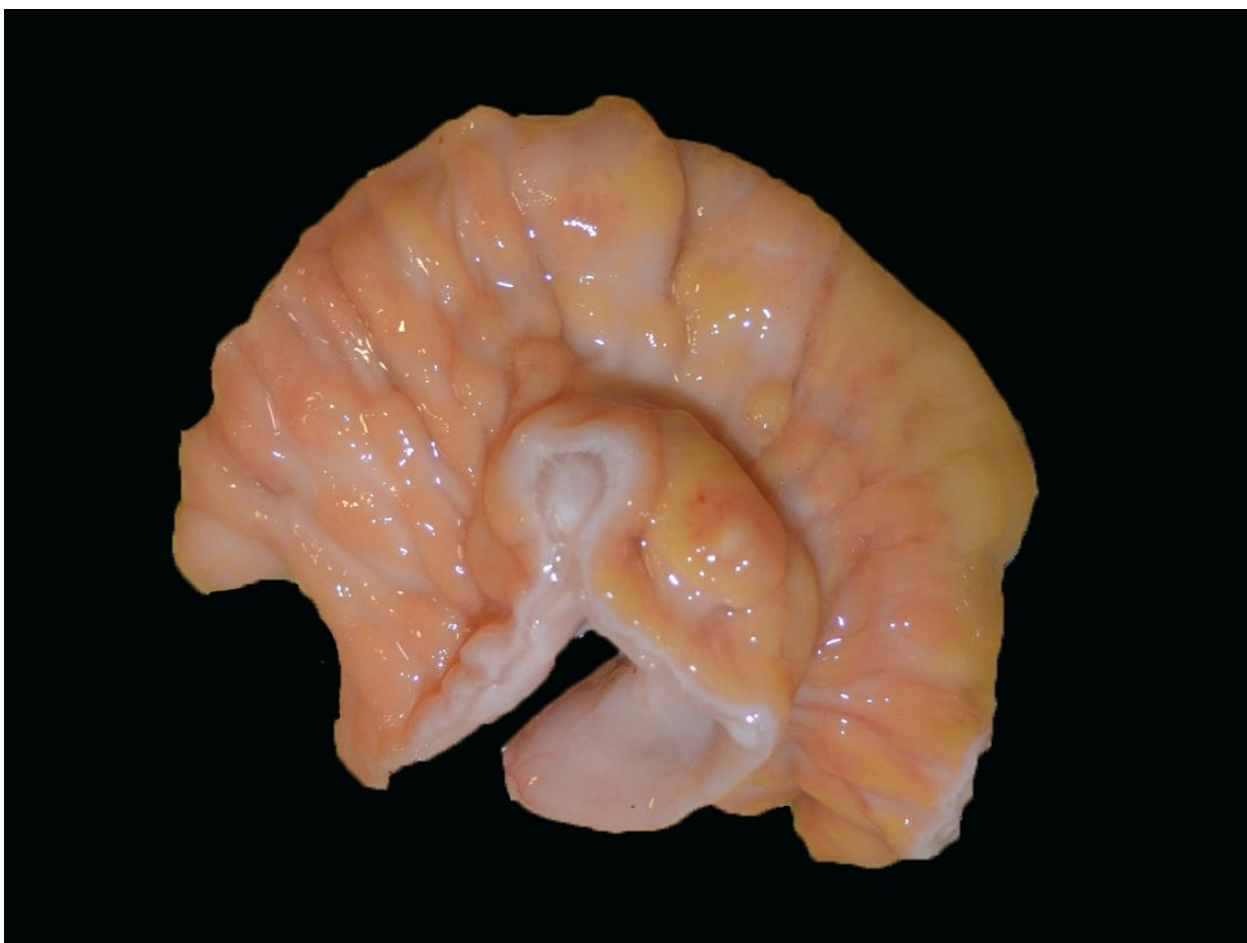


Figure 1. Small intestine, mucosal surface.

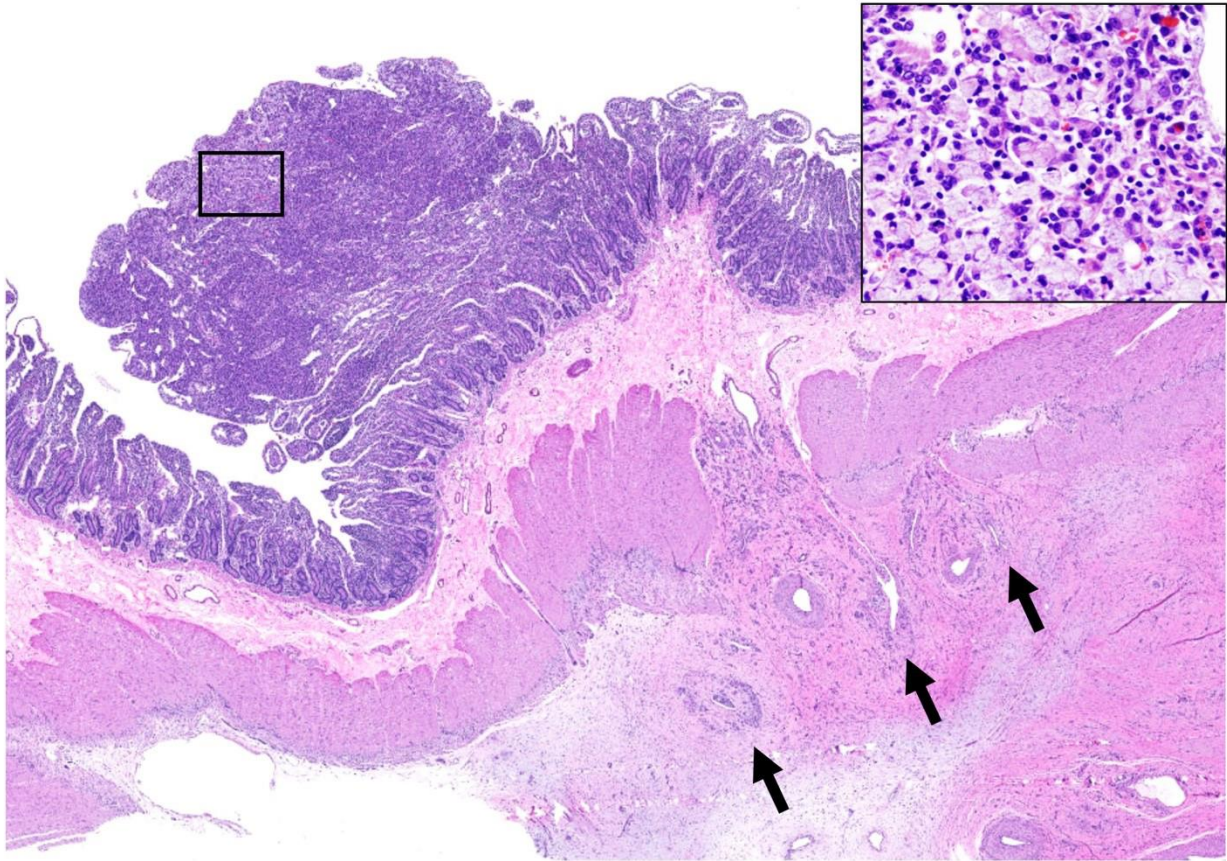


Figure 2. Small intestine. Hematoxylin and eosin; 1.25X and 20X (inset).

Microscopic description: Corresponding to the areas of mucosal thickening, the small intestinal mucosa is multifocally effaced by a poorly demarcated, non-encapsulated, exophytic and infiltrative neoplasm that replaces the normal villous architecture. The neoplasm is composed of polygonal cells arranged in solid aggregates and glands and supported by fibrovascular stroma. Neoplastic cells have variably distinct cell borders, moderate to abundant amount of basophilic to eosinophilic cytoplasm, a round to oval, peripheral nucleus with finely stippled chromatin, and 1-2 distinct nucleoli. Frequently, the cytoplasm of numerous neoplastic cells is expanded by abundant amphophilic and finely fibrillar material that stains intensely with Alcian Blue (mucin) and peripheralizes the nucleus. Anisocytosis and anisokaryosis are moderate, and three mitotic figures are counted in 10 high power fields. Neoplastic cells frequently extend to the tunica submucosa and muscularis externa either as small nests or as individual cells delimited by marked fibrosis (desmoplasia). Neoplastic cell emboli are also

observed within the lumen of multiple lymphatic vessels. Similar neoplastic cells are identified along the intestinal serosa and in the mesenteric and tracheobronchial lymph nodes, uterine surface, and ovary.

Morphologic diagnosis: Intestinal adenocarcinoma with metastases to mesenteric and tracheobronchial lymph nodes, uterus and ovary.

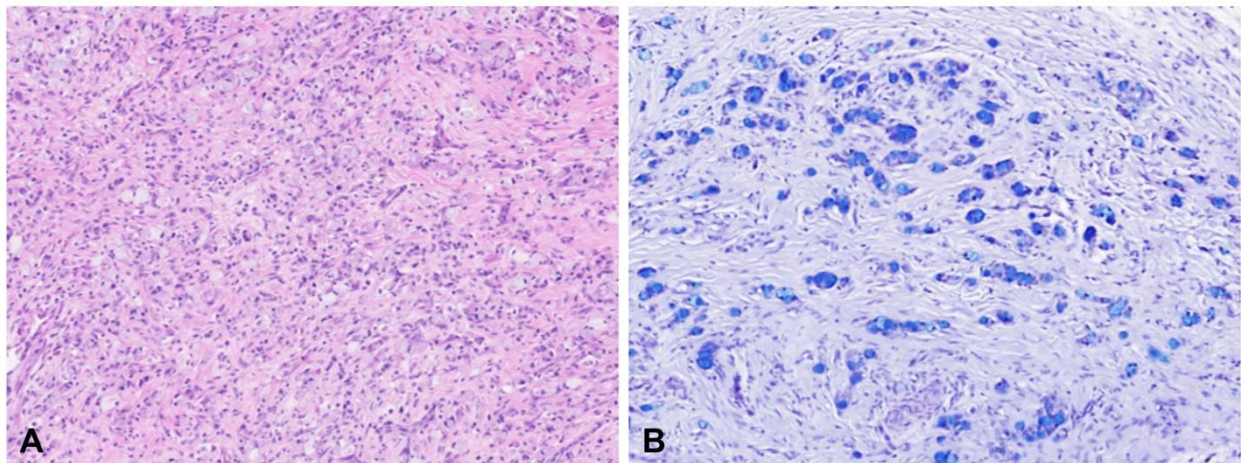


Figure 3. Small intestine (submucosa). Hematoxylin and eosin (A; 10X) and Alcian Blue (B; 20X)

Typical gross findings:

- A single, firm, pale and annular thickening of the intestinal wall, multiple masses, or poorly defined mucosal thickening due to mucosal spread of the neoplasm
- An intraluminal mass protruding from the intestinal wall

Typical microscopic findings:

- The neoplasm consists of proliferation of epithelial cells arranged in irregular glands or ducts.
- Neoplastic cells develop from the crypt epithelium and then infiltrate underlying layers as individualized cells or acini. Deep invasion is often present and small numbers of neoplastic cells surrounded by marked fibroblastic response (desmoplasia) is commonly seen.

- The neoplastic cells are columnar to cuboidal and frequently are markedly dysplastic. Acini may contain goblet cells and accumulation of eosinophilic material within the acinar lumen. The neoplastic cells contain vesicular nuclei with prominent nucleoli.

Discussion:

Adenocarcinomas are reportedly the most common intestinal neoplasm in domestic animals, except in cats, in which gastrointestinal lymphomas occur more frequently (Munday et al. 2017). In sheep and cattle, the prevalence of intestinal adenocarcinomas varies depending on the geographical region (Munday et al. 2017). This variability could be due to exposure to environmental carcinogens including plants such as bracken fern, genetic predisposition or infection (Kelly et al. 2015, Munday et al. 2017). Intestinal adenocarcinomas in dogs, cats and sheep often metastasize. In dogs, these neoplasms are typically advanced at presentation, with regional nodal and/or distant metastases most commonly identified in the peritoneum and liver (Munday et al. 2017). Similarly, feline intestinal adenocarcinomas metastasize rapidly and most often to the regional lymph nodes and peritoneum. Some cases of pulmonary metastases have also been reported in this species. Ovine intestinal adenocarcinomas are particularly infiltrative and metastases to the mesenteric lymph nodes are common. During meat inspection of reportedly healthy slaughtered sheep, 42 out of 50 animals (84%) were diagnosed with intestinal adenocarcinoma. In these sheep, distant metastases were confirmed in 26 out of 50 individuals (52%) (Munday et al. 2017).

There are several reported cases of intestinal adenocarcinoma in goats as well (Wohlsein and Kuczka 1989, Haibel 1990, Pérez et al. 1998, Löhr 2012). In these reports, the tumors were found in the jejunum, ileum or ileocecal junction with or without involvement of mesenteric lymph nodes (Pérez et al. 1998, Löhr 2012). In the goat of this report, the primary neoplasm was in the ileum and metastases were identified throughout the intestinal serosa, in the mesenteric and tracheobronchial lymph nodes, uterine serosa, and ovary.

References

- Haibel G.K. 1990. Intestinal adenocarcinoma in a goat. J. Am. Vet. Med. Assoc. 196:326-328.
- Kelly P.A., Toolan D., Hans J. 2015. Intestinal adenocarcinoma in a herd of farmed sika deer (*Cervus nippon*): A novel syndrome. Vet. Pathol. 52:193-200.
- Löhr C.V. 2012. One hundred two tumors in 100 goats (1987–2011). Vet. Pathol. 50:668-675.
- Munday J.S., Löhr C.V., Kiupel M. 2017. Tumors of the alimentary tract, 563-568. In: Meuten D.J. (Ed) Tumors in Domestic Animals. 5th ed. Wiley Blackwell, Ames.
- Pérez V., Corpa J.M., Garcia Marin J.F. 1998. Adenocarcinoma of the small intestine in a goat. J. Comp. Path. 119:311-316.
- Wohlsein P., Kuczka A. 1989. Case report: adenocarcinoma of the intestines in a goat. Dtsch. Tierärztl. Wochenschr. 96:222-223.

*The Diagnostic Exercises are an initiative of the **Latin Comparative Pathology Group (LCPG)**, the Latin American subdivision of The Davis-Thompson Foundation. These exercises are contributed by members and non-members from any country of residence. Consider submitting an exercise! A final document containing this material with answers and a brief discussion will be posted on the CL Davis website (http://www.cldavis.org/diagnostic_exercises.html).

Associate Editor for this Diagnostic Exercise: Mariano Carossino
Editor-in-chief: Claudio Barros