

# Diagnostic Exercise

## From The Davis-Thompson Foundation\*

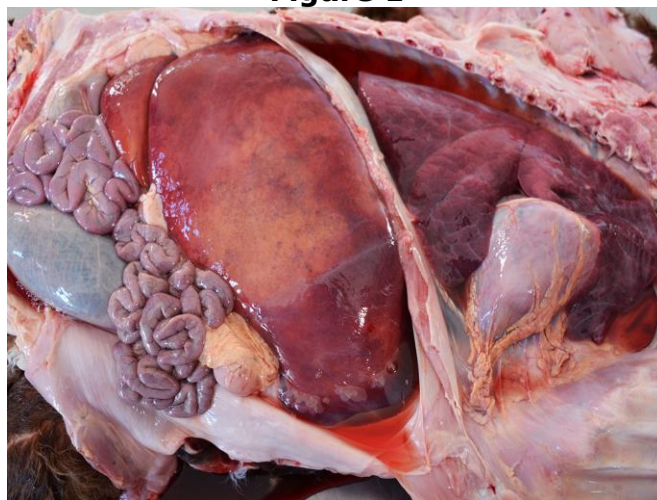Case #: **164** Month: **April** Year: **2021**

**Contributors:** Luan Cleber Henker\*, DVM, MS, PhD candidate; Marina Paula Lorenzetti, DVM, MS, PhD candidate; Saulo Petinatti Pavarini, DVM, MS, Doctor in Veterinary Pathology, Associate Professor, Veterinary Pathology Laboratory, Universidade Federal do Rio Grande do Sul (UFRGS), Porto Alegre, Rio Grande do Sul, 91540-000, Brazil. \*Corresponding author: [luanchenker@gmail.com](mailto:luanchenker@gmail.com).

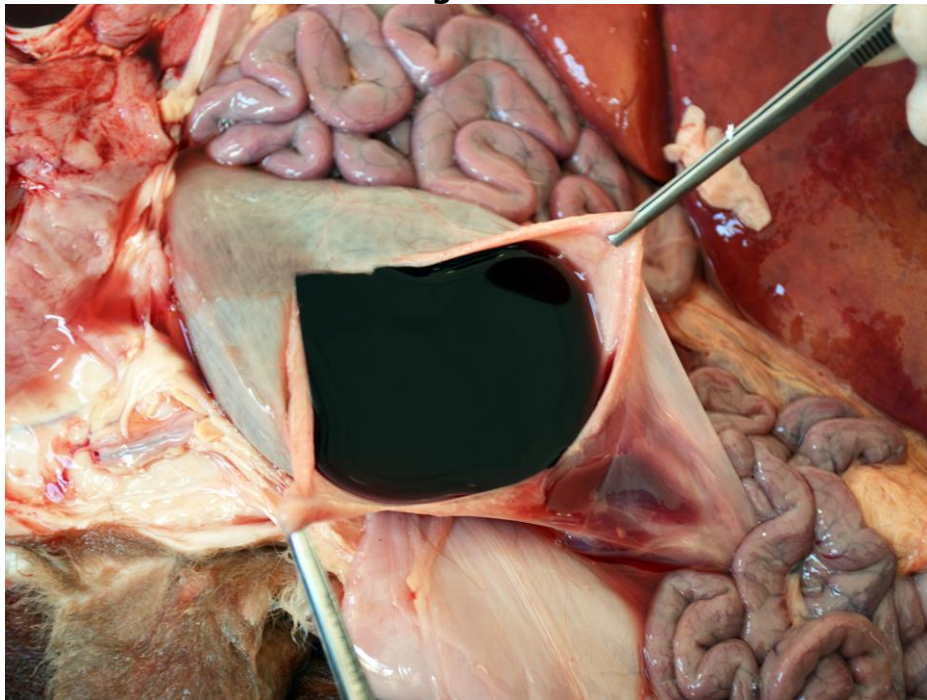
**Clinical History:** A crossbred, stillborn bovine fetus, with nine months of gestation, was submitted for postmortem examination. The dam that aborted was a 2-year-old heifer that did not have any additional clinical signs. The owner observed several late-term abortions and stillbirths in this farm during the referred calving season.

**Necropsy and Microscopic Findings:** Necropsy findings included moderate accumulation of light red fluid in the abdominal and thoracic cavities, mild hemoglobin imbibition, as well as collapsed lungs (Figure 1). The liver was markedly enlarged, had rounded edges, and moderate, diffuse yellow discoloration. The gallbladder was filled with thick, grumous bile, and the spleen was moderately enlarged. The kidneys had moderate diffuse dark red discoloration, and the urinary bladder was distended with dark-red urine (Figure 2). The grey matter of the brain and the spinal cord was markedly pink-red discolored (Figure 3). Squashes of the spleen and brain were prepared and routinely stained with PanóticoRápido® (Laborclin, Brazil) (Figure 4).

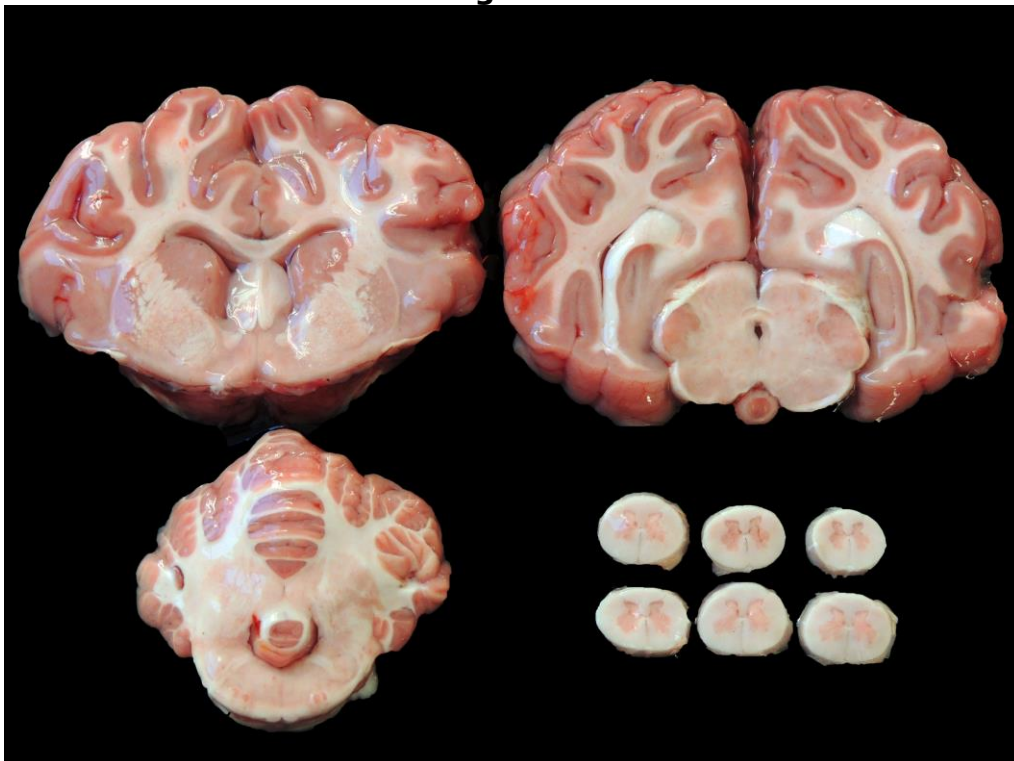
**Figure 1**



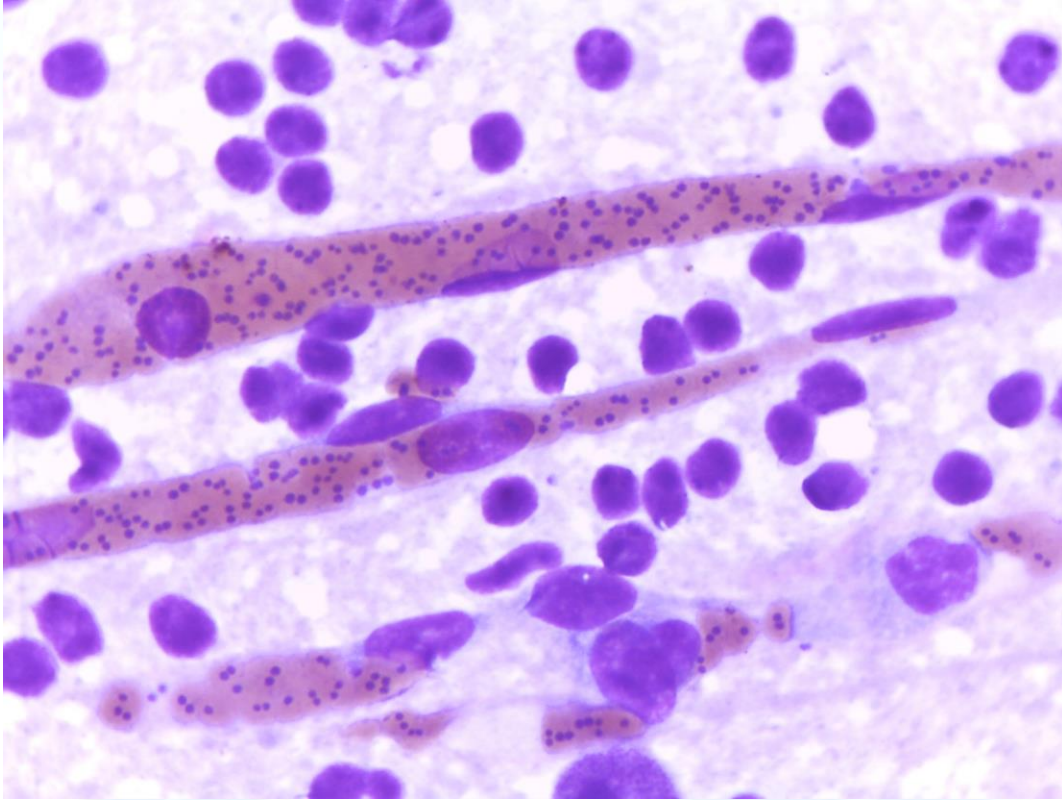
**Figure 2**



**Figure 3**



**Figure 4**



**Follow up questions:**

- *Name of the condition:*
- *Etiology:*
- *Mechanism of pathogen transmission in this case:*

**Associate Editor for this Diagnostic Exercise:** Ingeborg Langohr.

**Editor-in-chief:** Claudio Barros

\*The Diagnostic Exercises are an initiative of the Latin Comparative Pathology Group (LCPG), the Latin American subdivision of The Davis-Thompson Foundation. These exercises are contributed by members and non-members from any country of residence. - Consider submitting an exercise! - A final document containing this material with answers and a brief discussion will be posted on the CL Davis website ([http://www.cldavis.org/diagnostic\\_exercises.html](http://www.cldavis.org/diagnostic_exercises.html)).