



# Diagnostic Exercise

## From The Davis-Thompson Foundation\*

Case #: 160 Month: February Year:2021

Answer sheet

**Title:** Avian pox, candidiasis and bacterial infection in a yellow-naped Amazon parrot

**Contributors:** Viviana Gonzalez, BVSc (hons), MNR, PhD, Francisco Uzal, DVM, MSc, PhD, DACPV; California Animal Health and Food Safety Laboratory, San Bernardino Branch, University of California-Davis, USA. [fauzal@ucdavis.edu](mailto:fauzal@ucdavis.edu)

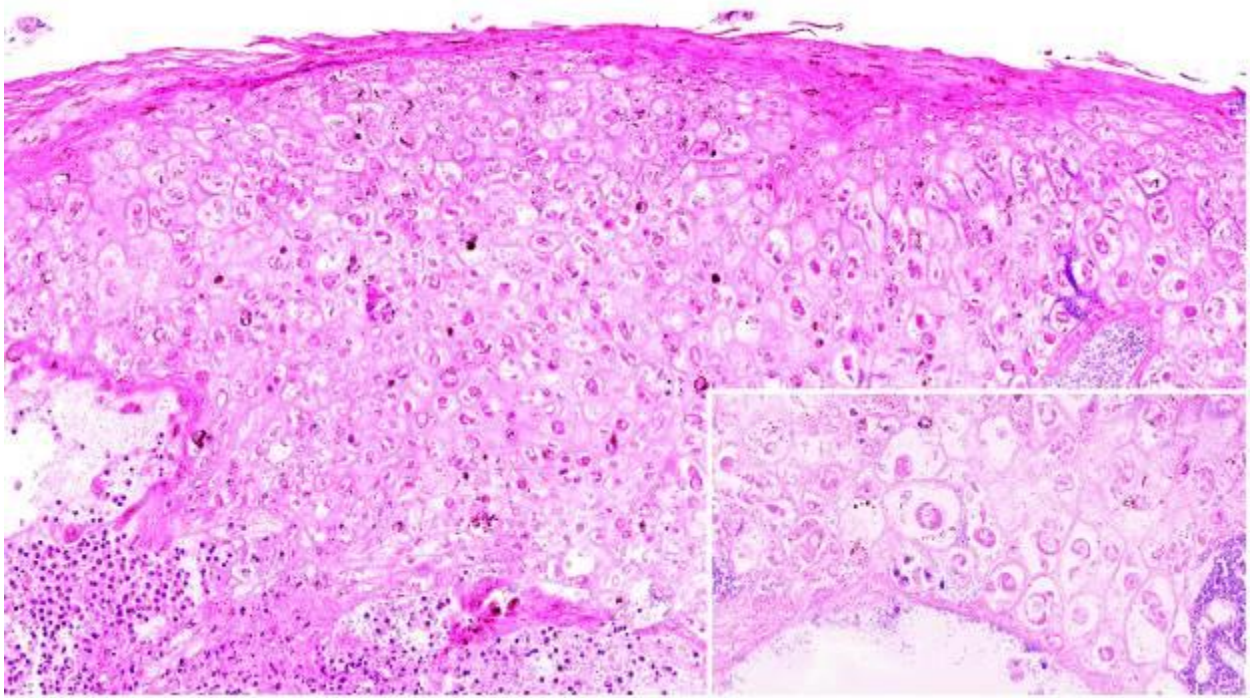
**Clinical History:** 8-week-old, male Yellow-naped Amazon parrot (*Amazona auropalliata*) with history of a white granular plaques in the caudal palate and oropharyngeal mucosa.

**Necropsy Findings:** There was severe dilation of the esophagus and proventriculus (about 3-fold) and their contents were semi-liquid, grey and finely granular. The soft palate, pharynx, tongue and proximal esophagus had numerous multifocal to coalescing, ~2-3mm diameter, round to irregular, umbilicated white foci with elevated borders. A few of these foci were also present in the mucosa of the distal esophagus and the crop (Fig. 1).

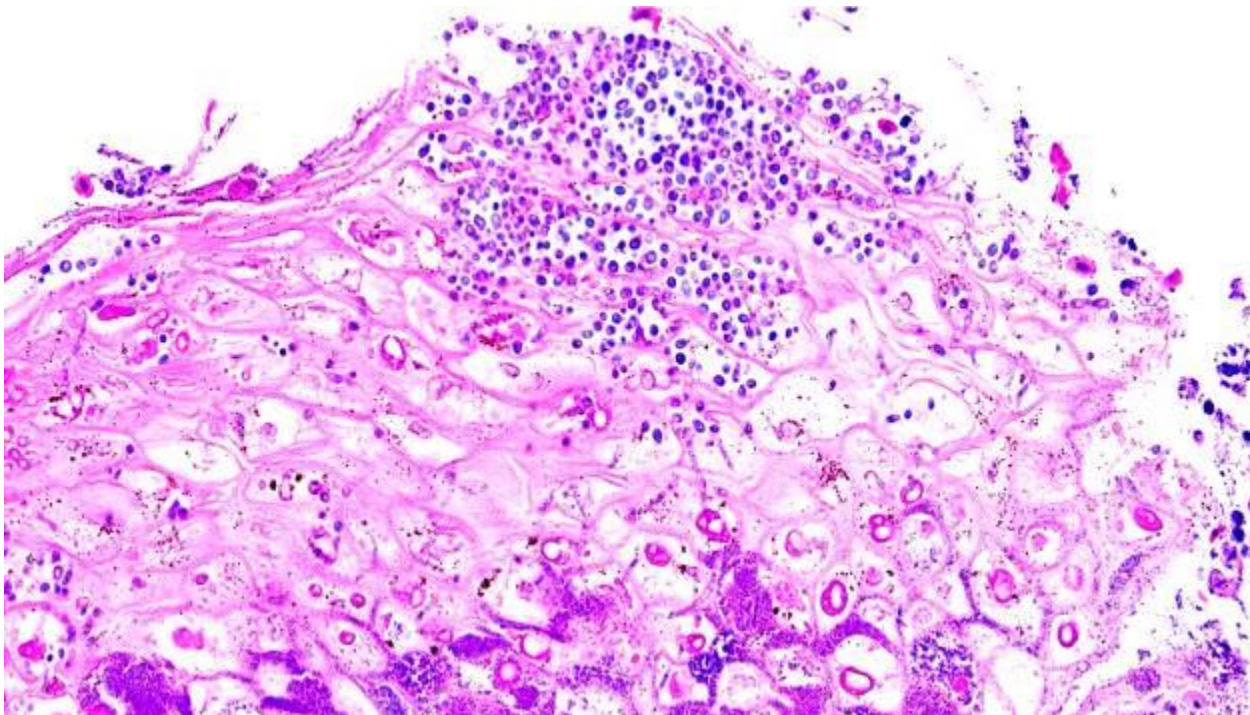
**Follow-up questions:** Microscopic description, Morphologic diagnosis, and three possible etiologies.

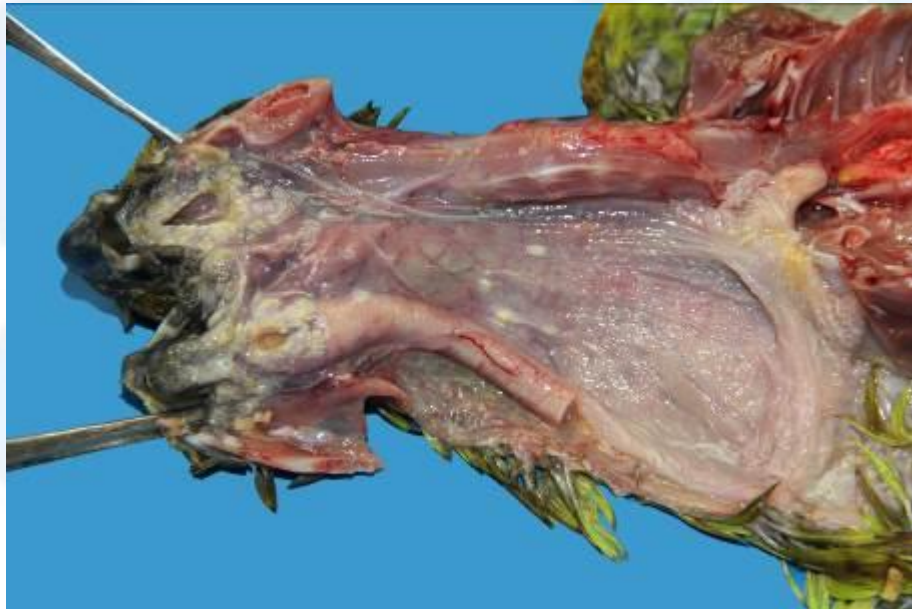

Figure 1. Gross findings



**Figure 2. H&E**



**Figure 3. H&E**

**Microscopic description:** Pharynx. The epithelium is multifocally and markedly hyperplastic, hyperkeratotic and infiltrated by large numbers of degranulating heterophils. Most keratinocytes are swollen and contain a single prominent intracytoplasmic eosinophilic inclusion body (Bollinger bodies) (Fig. 2). There is multifocal ulceration of the epithelium and necrotic epithelial cells are sloughed off into the lumen. Coccobacillary and coccoid bacterial



colonies are observed filling the intercellular spaces (Fig. 3). Multiple aggregates of ~3-4 µm long, lightly basophilic thin walled yeast cells (blastospores/blastoconidia) and ~3µm wide, irregularly septated, slender short chains with parallel walls (pseudohyphae) are observed overlying the necrotic epithelium (Fig. 3).

**Morphologic diagnosis:** Glosso-pharyngo-esophagitis, proliferative, ulcerative, multifocal to coalescing, severe, chronic, with intracytoplasmic inclusion bodies, hydropic degeneration, intralesional coccobacilli, yeasts and pseudohyphae.

**Etiology:** Avian poxvirus; *Candida* spp; mixed bacteria.

**Other possible etiologies:** Vitamin A deficiency, *Trichomonas* spp., *Capillaria* spp. spp. These etiologies were ruled out based on histology.

**Comments:** Avian poxvirus is one of the most common viruses known to infect up to 329 species of birds in 76 bird families, including psittacids, causing a diphtheritic and a cutaneous form (van Riper and Forrester, 2007; Carulei et al. 2017). Grossly, the diphtheritic form leads to proliferative, caseo- or fibrino-necrotizing lesions of mucosas, usually in the upper alimentary tract, and can cause higher mortality compared to the cutaneous form. The diphtheritic form of avian pox is often complicated by fungal or bacterial opportunistic infections (Boulianne, 2013), as it was the case with this yellow-naped Amazon parrot. Key histological features of poxviral infection include marked mucosal hyperplasia, hydropic degeneration of keratinocytes, and prominent, eosinophilic, intraepithelial inclusion bodies denominated “Bollinger bodies” which represent sites of synthesis and packing of virus particles (Boulianne, 2013). In a retrospective study of avian pathology laboratory accessions, the diphtheritic form was more often diagnosed than the cutaneous form in young psittacids (Nemeth et al. 2016).

In birds, the most frequently isolated yeast is *Candida* spp., which induces severe mucosal hyperplasia, with catarrhal inflammation, ulceration and parakeratosis of the upper gastrointestinal tract. Although some of these lesions can also be caused by poxvirus, it is possible that in this case, poxvirus was the initiating infection that allowed for *Candida* spp. and bacteria to become secondary invaders.

The upper alimentary lesions in this parrot eventually lead to septicemia, causing severe nephritis and myocarditis which were considered to be the ultimate cause of death (not shown).

#### References:

- Boulianne M. 2013. Viral diseases. In: Avian Disease Manual. 7th ed. Jacksonville, FL: American Association of Avian Pathologists, Inc.: 46-49.
- Carulei O, Douglass N, and Williamson AL. 2017. Comparative analysis of avian poxvirus genomes, including a novel poxvirus from lesser flamingos (*Phoenicopterus minor*), highlights the lack of conservation of the central region. BMC Genomics, 18, 947.
- Nemeth N, Gonzalez-Astudillo V, Oesterle PT, and Howerth EW. 2016. A 5-Year retrospective review of avian diseases diagnosed at the Department of Pathology, University of Georgia. J Comp. Path. 155: 105-120.
- van Riper C, and Forrester DJ. 2007. Avian pox. In: Infectious Diseases of Wild Birds, NJ Thomas, DB Hunter, CT Arkinson, Eds., Blackwell Publishing, Iowa, pp. 131-176.

\*The Diagnostic Exercises are an initiative of the Latin Comparative Pathology Group (LCPG), the Latin American subdivision of The Davis-Thompson Foundation. These exercises are contributed by members and non-members from any country of residence. - Consider submitting an exercise! - A final document containing this material with answers and a brief discussion will be posted on the CL Davis website ([http://www.cldavis.org/diagnostic\\_exercises.html](http://www.cldavis.org/diagnostic_exercises.html)).

**Associate Editor for this Diagnostic Exercise:** Francisco A. Uzal.  
**Editor-in-chief:** Claudio Barros

L  
C  
P  
G

