

# Diagnostic Exercise

## From The Davis-Thompson Foundation\*

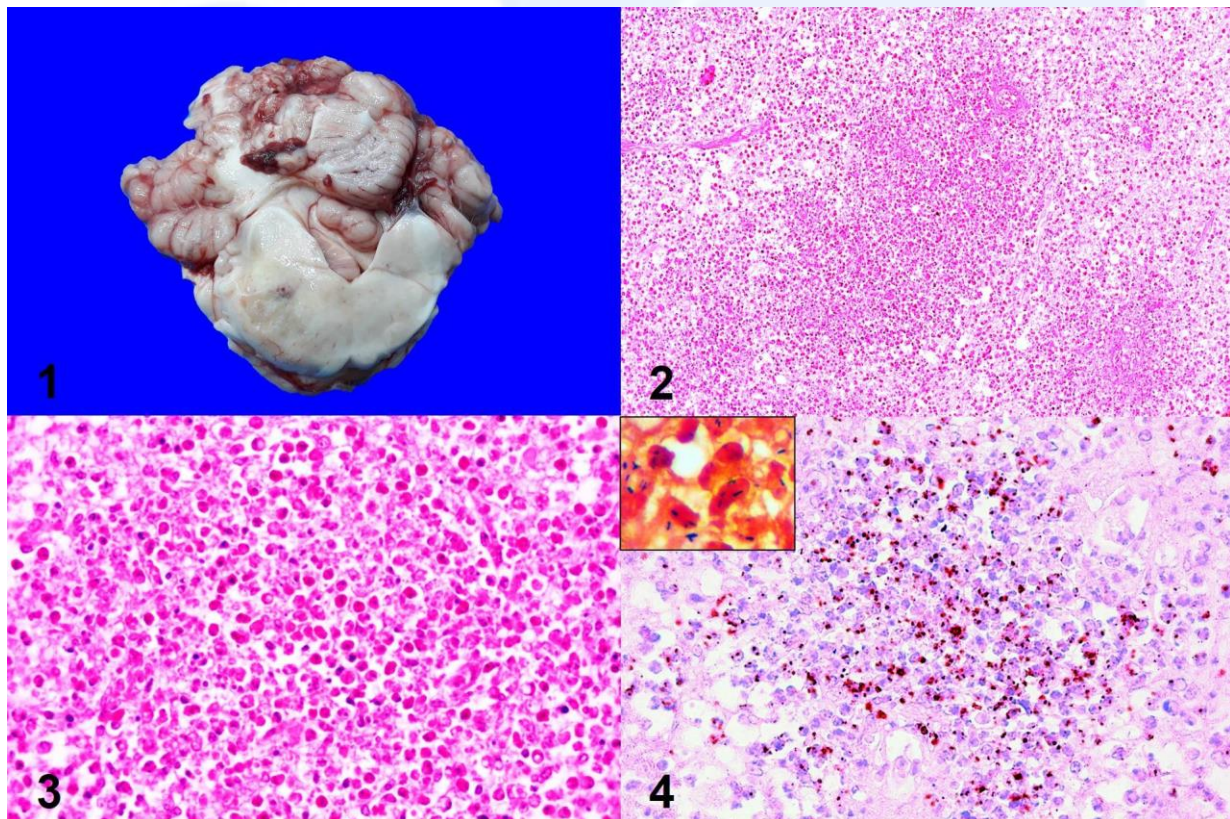
### Question Sheet

Case #: **170** Month: **August** Year: **2021**

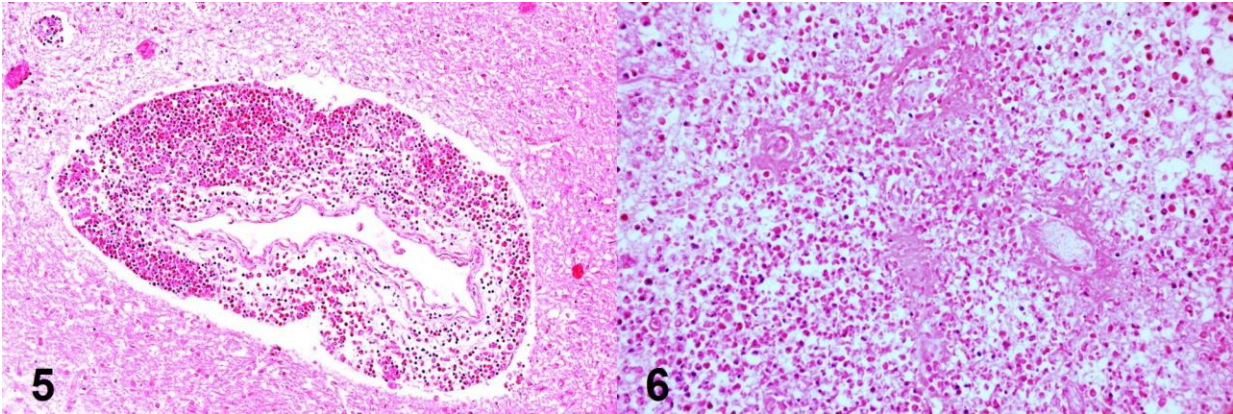
**Contributors:** Matías A. Dorsch, DVM, MSc and Federico Giannitti<sup>1</sup>, DVM. Instituto Nacional de Investigación Agropecuaria (INIA), La Estanzuela, Colonia, Uruguay. <sup>1</sup> [fgiannitti@inia.org.uy](mailto:fgiannitti@inia.org.uy).

**Clinical History:** 4-year-old Holstein cow with a history of unilateral (right side) facial paralysis, keratitis, drooping of the right ear, head tilt, circling, stiffness of the right limbs, tremors, and recumbency.

**Necropsy Findings:** The left side of the brainstem was swollen, multiple coalescing areas of the neuroparenchyma in this region were soft, tan-brownish, and slightly depressed on cut section (malacia).



**Figure 1:** Cross section of the cerebellum and brainstem at the level of the pons depicting the lesions described as necropsy findings, caudal view. **Figure 2:** Brainstem, hematoxylin and eosin (H&E), 20x. **Figure 3:** Brainstem, H&E, 20x. **Figure 4:** Immunohistochemistry, 40x. *Inset:* Gram stain, 50x.



**Figure 5:** Brainstem, H&E, 20x. **Figure 6:** Brainstem, H&E, 40x.

**Follow-up questions:**

- (i) *Morphologic diagnosis?*
- (ii) *Differential diagnosis/es?*
- (iii) *Etiologic diagnosis?*
- (iv) *cause?*
- (v) *Name of the disease.*

\*The Diagnostic Exercises are an initiative of the Latin Comparative Pathology Group (LCPG), the Latin American subdivision of The Davis-Thompson Foundation. These exercises are contributed by members and non-members from any country of residence. - Consider submitting an exercise! - A final document containing this material with answers and a brief discussion will be posted on the CL Davis website ([http://www.cldavis.org/diagnostic\\_exercises.html](http://www.cldavis.org/diagnostic_exercises.html)).

**Associate Editor for this Diagnostic Exercise:** Ingeborg Langohr  
**Editor-in-chief:** Claudio Barros