



# Diagnostic Exercise

## From The Davis-Thompson Foundation\*

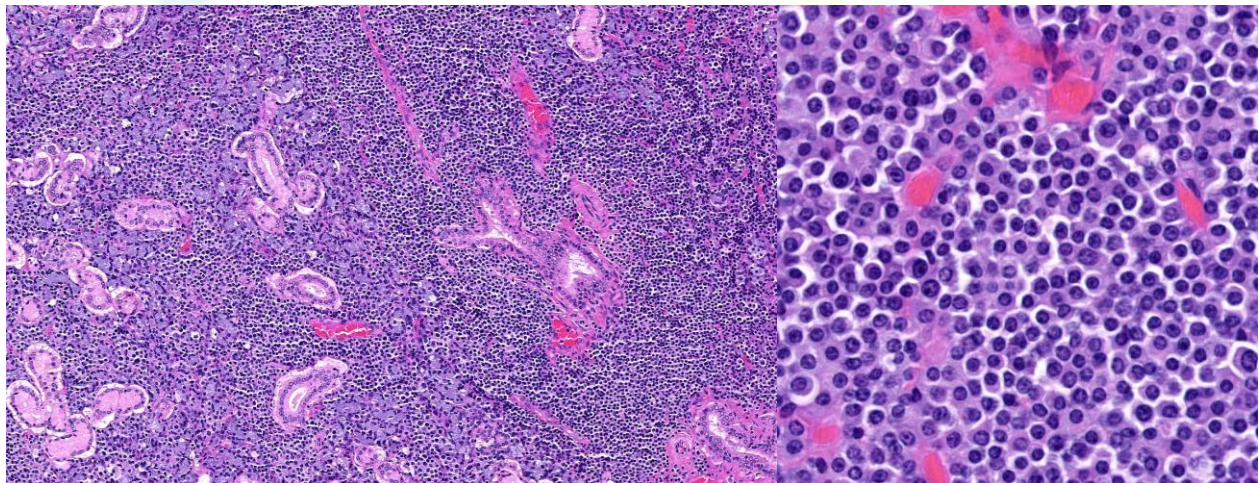
Case #: 152 Month: October Year: 2020

**Contributor:** Lillian Miller (Veterinary Student), Emi Sasaki (DVM), Anke C. Stöhr (DVM), Thomas N. Tully Jr. (DVM, MS, DABVP (Avian), ECZM (Avian)) & Dawn Evans (DVM, DACVP); School of Veterinary Medicine, Louisiana State University, Baton Rouge, LA

**Clinical History:** A 1.5-year-old, intact female Syrian hamster (*Mesocricetus auratus*) presented for bilaterally closed eyes, anorexia, adipsia, and lethargy with watery stool or vaginal discharge for the previous two days. The animal had been presented four months prior with similar clinical signs. At that time, there were no significant changes on bloodwork and radiographs were unremarkable; however, mild bicavitary effusion, a single cystic lesion of the liver and a single cystic abdominal lymph node were found on ultrasound. This time, physical exam revealed dehydration, weight loss (35% body weight), yellow vaginal discharge, a mass at the cranial thorax, and respiratory distress. A complete blood count revealed leukopenia with neutropenia. Due to poor prognosis, the hamster was humanely euthanized.

**Necropsy Findings:** The hamster was in thin body condition (3.5/9). A subcutaneous, round, loosely attached mass measuring approximately 1 cm in diameter was present in the ventral neck. The mass had raised, pale tan, nodular areas that were well demarcated from smooth, pale pink areas. On cut surface, the mass was diffusely pink.

**Microscopic Images:**



Figures 1+2

**Follow-Up Questions:** Morphologic Diagnosis; Immunohistochemical stains

\*The Diagnostic Exercises are an initiative of the **Latin Comparative Pathology Group (LCPG)**, the Latin American subdivision of The Davis-Thompson Foundation. These exercises are contributed by members and non-members from any country of residence. Consider submitting an exercise! A final document containing this material with answers and a brief discussion will be posted on the CL Davis website ([http://www.cldavis.org/diagnostic\\_exercises.html](http://www.cldavis.org/diagnostic_exercises.html)).

**Associate Editor for this Diagnostic Exercise:** Ingeborg Langohr  
**Editor-in-chief:** Claudio Barros